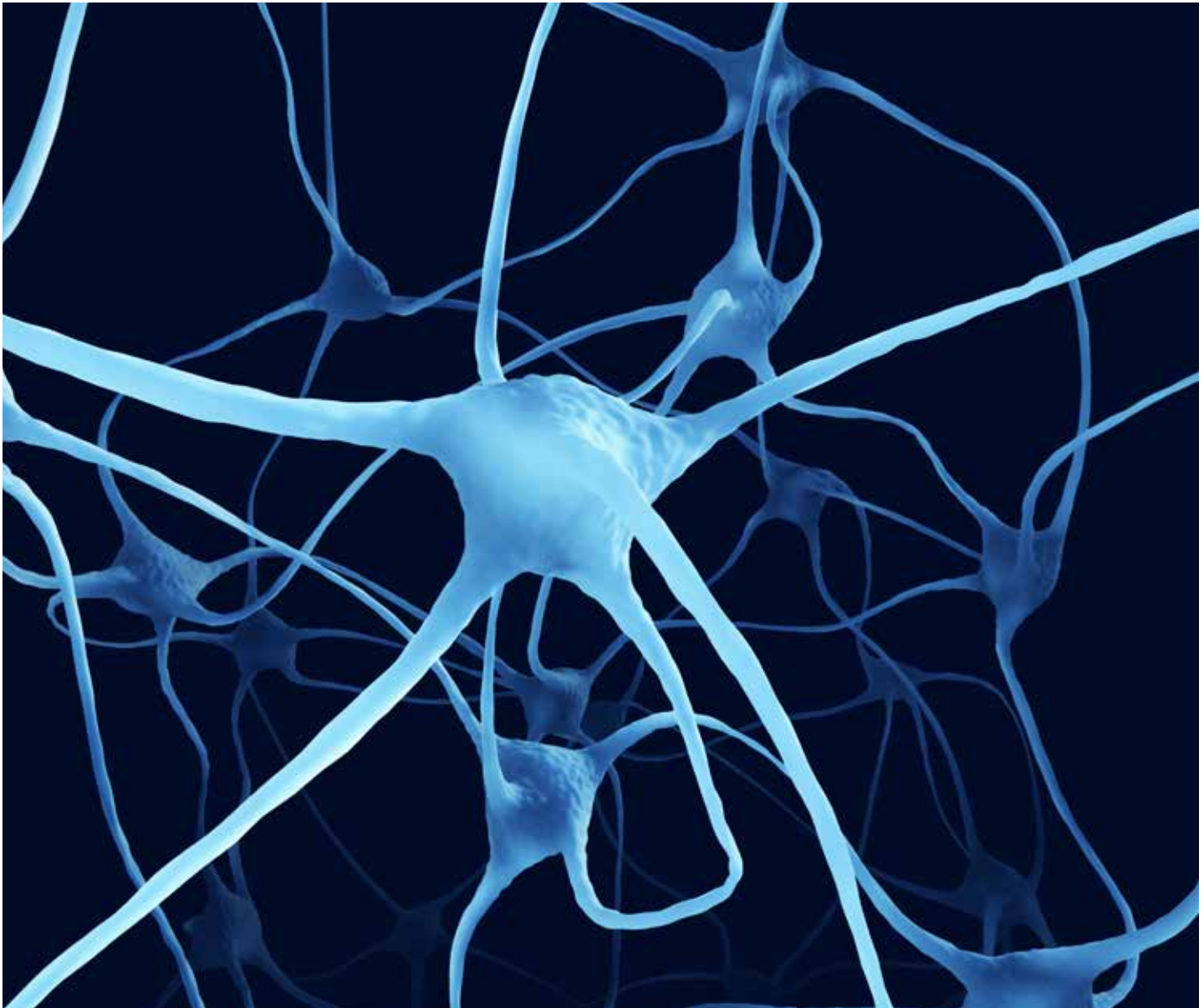

# CASEBOOK

VOLUME 26 | ISSUE 1 | MAY 2018

SOUTH AFRICA



## Sciatic nerve injury but was it negligent?

A CLAIM IS RECEIVED ALLEGING IATROGENIC NERVE DAMAGE

### From the case files

#### **FAILURE TO ACT ON LOWER BACK PAIN**

What red flags were missed by both GP and hospital?

#### **STRONG RECORD-KEEPING – STRONG DEFENCE**

Alleged negligence leads to a claim and regulatory hearing.

#### **NO RENAL REVIEW**

Regular reviews are missed during long-term naproxen use.

# CPD Questions

VOLUME 26, ISSUE 1

CPD ACCREDITATION BY SAMA

**1) Achilles tendon ruptures are often missed by non-specialists.**

**It happens in:**

- (a) 20% of cases
- (b) 35% of cases
- (c) 50% of cases
- (d) 80% of cases

**2) The documentation of examinations should always include:**

- (a) Positive findings only
- (b) Negative findings only
- (c) Positive and negative findings
- (d) Whatever you have time to include

**3) A missed diagnosis is:**

- (a) Negligent – it is a clear breach of duty
- (b) Not negligent at all – we all make mistakes
- (c) Not necessarily negligent, if practice does not fall below a reasonable standard

**4) Detailed record-keeping and use of a chaperone:**

- (a) Is over-cautious and defensive
- (b) Provides corroborative evidence of practice
- (c) Makes no difference to the outcome of a case

**5) Abnormal blood results:**

- (a) Should be reviewed by the clinician who requested the test
- (b) Do not need managing according to a patient's existing condition
- (c) Need safety nets, to ensure requesting and reviewing clinicians know where their own responsibilities lie

**6) Missed opportunities to follow up abnormal blood results:**

- (a) Is 100% pure negligence
- (b) Only negligent if the patient has a chronic disease
- (c) Is not negligent if it makes no clinical difference to the patient's outcome

**7) A patient with back pain:**

- (a) Is a straightforward and routine diagnosis
- (b) Is not likely to be affected by any delay in treatment
- (c) Needs to be checked for red flags and other signs of serious underlying problems

**8) If a patient continues to have problems after a specialist assessment:**

- (a) It is up to the consulting clinician, whether GP or specialist, to arrange further assessment
- (b) It is purely a concern for that specialist
- (c) A sign of a problematic, time-wasting patient

**9) Annual medication reviews:**

- (a) Are an administrative burden
- (b) Should only be performed for high-risk patients
- (c) Are important for all patients, particularly those on long-term medications

**10) Open and honest communication:**

- (a) Is an admission of liability and never a good idea
- (b) Is a professional responsibility and can help rebut complaints and claims
- (c) Makes no difference if a complication occurs – I'm automatically negligent

**TO COMPLETE YOUR CPD QUESTIONNAIRE PLEASE VISIT OUR ONLINE LEARNING PLATFORM, PRISM  
GO TO: [MEDICALPROTECTION.ORG/PRISM](https://www.MEDICALPROTECTION.ORG/PRISM)**

After submission, you can check the answers and print your certificate.

# What's inside...

## Every issue



### Welcome

Dr Marika Davies, Editor-in-Chief of Casebook, welcomes you to this edition and comments on some topical issues.

### Over to you

What did you think about the last issue of Casebook? All comments and suggestions welcome.

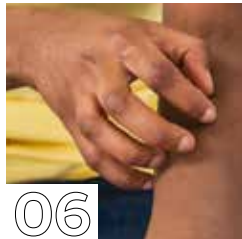## Case reports



05

### Wrongly reassured over swollen ankle

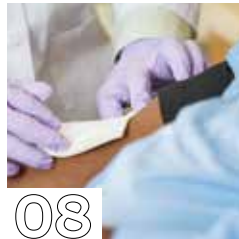A patient claims his diagnosis was delayed – but was the GP in the clear?



06

### A missed diagnosis but no negligence

Dermatologist Dr H is faced with a claim after a missed scabies diagnosis.



08

### No renal review

Regular reviews are missed during long-term naproxen use – and Mr J suffers renal impairment.



10

### Failure to act on lower back pain

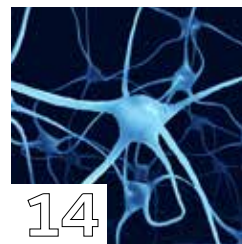What red flags were missed by both GP and hospital?



13

### A nitrofurantoin problem

No medication reviews or repeat tests lead to a claim.



14

### Sciatic nerve injury but was it negligent?

A claim is received alleging iatrogenic nerve damage – but was GP Dr L negligent?



16

### Strong record-keeping – strong defence

Alleged negligence during surgery leads to both a claim and regulatory hearing.

Opinions expressed herein are those of the authors. Pictures should not be relied upon as accurate representations of clinical situations. © The Medical Protection Society Limited 2018. All rights are reserved.

ISSN 1366 4409

Casebook is designed and produced twice a year by the Communications Department of the Medical Protection Society (MPS). Regional editions of each issue are mailed to all MPS members worldwide.

GLOBE (logo) (series of 6)® is a registered UK trade mark in the name of The Medical Protection Society Limited.

The Medical Protection Society Limited ("MPS") is a company limited by guarantee registered in England with company number 36142 at Level 19, The Shard, 32 London Bridge Street, London, SE1 9SG.

MPS is not an insurance company. All the benefits of membership of MPS are discretionary as set out in the Memorandum and Articles of Association. MPS® and Medical Protection® are registered trademarks.

Cover: ©BeholdingEye/GettyImages

Get the most from your membership...



Visit our website for publications, news, events and other information: [medicalprotection.org](http://medicalprotection.org)



Follow our tweets at: @MPS\_medical



Top tips in the palm of your hand – download the free MPS Advice app on the App Store or Google Play

## Editorial team



**DR MARIKA DAVIES**  
EDITOR-IN-CHIEF



**GARETH GILLESPIE**  
EDITOR



**DR JANET PAGE**  
EDITORIAL CONSULTANT



**ANTOINETTE COLTSMANN**  
EDITORIAL CONSULTANT

## Case report writers



**DR ANNA FOX**



**DR SAM DRESNER**



**DR ELLEN WELCH**

### PRODUCTION

**Emma Senior** Corporate Design Manager  
**Conor Walsh** Senior Designer  
**Print** Blesston

**Please address all correspondence to:**  
Casebook Editor, Medical Protection, Victoria House, 2 Victoria Place, Leeds LS11 5AE,  
United Kingdom  
[casebook@medicalprotection.org](mailto:casebook@medicalprotection.org)

## Welcome

**DR MARIKA DAVIES**  
EDITOR-IN-CHIEF



**G**iven the nature of our work, it is to be expected that the focus of Casebook over the years has been on medicolegal jeopardy, along with expert advice and guidance on how to avoid these pitfalls occurring in your own practice.

You are likely to be aware of some unwelcome developments in another area of medicolegal jeopardy over in the UK: gross negligence manslaughter, following the case of Dr Hadiza Bawa-Garba, the junior doctor struck off by the UK's General Medical Council (GMC).

This case has caused shockwaves throughout the profession and is also being keenly watched by practising clinicians around the world.

We are continuing to fight hard against what is fast becoming an untenable level of scrutiny, blame and castigation for hard-working doctors. Of particular concern for both Medical Protection and the profession is the impact that the decision may have on creating an open, learning culture in healthcare, at a time when the profession is already marred by low morale and fear.

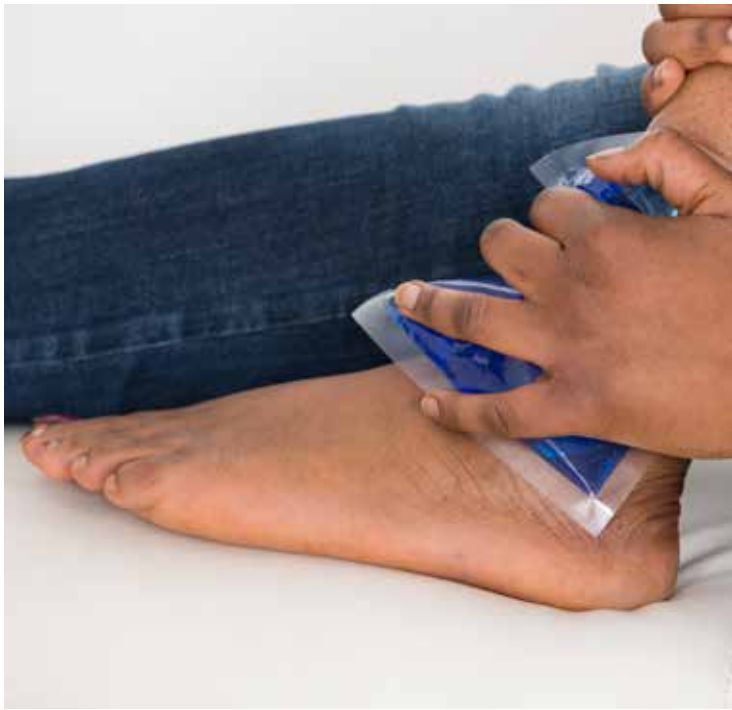There are no such criminal charges arising in this edition's usual collection of case reports, which feature the customary mix of settled cases and successful defences. This latest set of reports – based on real Medical Protection cases, with some facts altered to preserve confidentiality – have been expanded in length, to allow for more detail and greater exploration of the key issues and developments in each case.

In upcoming editions, we will also be expanding the case reports even further to provide you with more insight into the legal aspects of each case, to complement the clinical details that I know you enjoy reading. This wider focus on the complete narrative of a case has been prompted by your own feedback; many of you share a desire to get a more comprehensive understanding of the often complex and technical processes that comprise the passage of a case.

I hope you will enjoy this greater depth to your reading and I look forward to receiving your opinions. If you wish to get in touch on this or any other issue in Casebook, I would be happy to hear from you.

**Dr Marika Davies**  
**Editor-in-Chief**

[marika.davies@medicalprotection.org](mailto:marika.davies@medicalprotection.org)



©/jan-otto/gettyimages.co.uk

# Wrongly reassured over swollen ankle



BY DR ANNA FOX, GP

**M**r E, a 50-year-old accountant, was playing squash with a colleague after work and hurt his left ankle. He couldn't keep playing but he was able to walk, so he went home. The next day his ankle became quite swollen, so Mr E kept it on ice and took some ibuprofen.

He did not see a GP at the time because he was busy at work. He was still able to walk, although he had pain around the back of his ankle and heel. A month later, the swelling and aching around his ankle did not seem to be settling down, so he made an appointment with his GP, Dr N.

Dr N noted that his ankle had been very painful and swollen after the injury, although overall it was significantly better. She examined Mr E and found that his gait was antalgic. She documented mild swelling but no tenderness to the ankle, and noted that his ankle had full range of movement. She diagnosed a sprain and advised Mr E to rest the ankle, elevate it when he was sitting and to use a compression bandage in the daytime.

Mr E followed the advice but was getting very frustrated since his pain and swelling failed to improve. Two months later his pain worsened and he was finding it hard to fully weight bear. He went to the Emergency Department (ED) to see if he needed an x-ray. He wondered if he could have broken a bone with the initial injury and that was why his symptoms were not settling down.

The ED doctor noticed a swelling over his Achilles tendon and a weak plantar response to a Simmond's test. It was also noted that he was unable to stand on tiptoe.

A review by the fracture clinic the following day considered the Simmond's calf squeeze test to be normal, but again noted Mr E's inability to stand on tiptoes. A rupture of his Achilles tendon was suspected, and an ultrasound scan confirmed a complete tear with a significant gap.

Mr E's tendon healed but in an elongated fashion, affecting his ability to run and play sports. He made a claim against his GP, Dr N, alleging failure to diagnose a ruptured Achilles tendon, thus delaying treatment and adversely affecting his recovery.

## OUTCOME

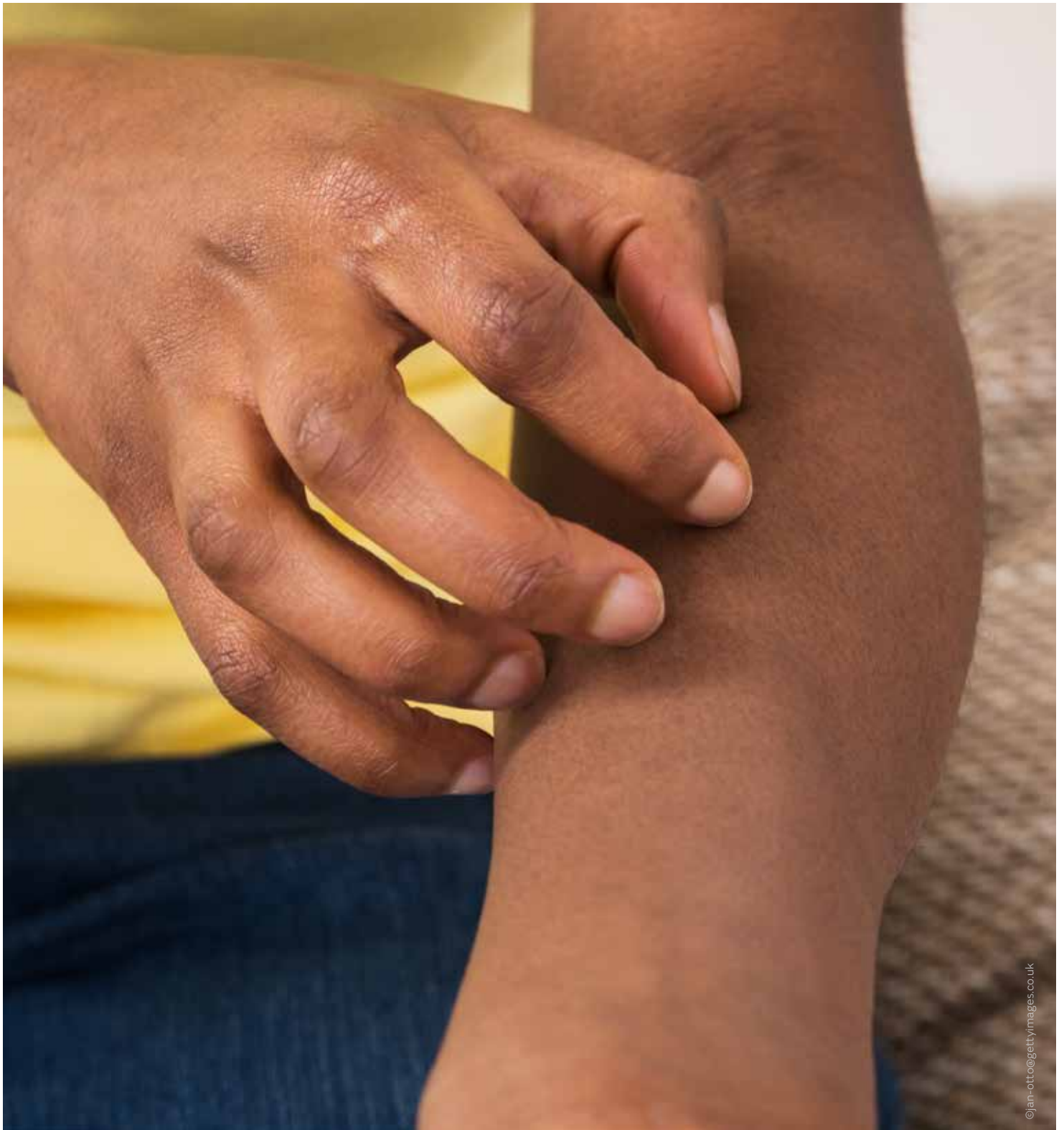
In this case, based on the medical records and the assessment of the legal team, Medical Protection was able to serve a letter of response denying liability. In the letter of response it was argued that it was reasonable for Dr N to diagnose an ankle sprain based on the history and her clinical examination. The letter highlighted that as the Simmond's test performed at the fracture clinic was normal, it therefore would likely have also been normal at the time of Dr N's examination. The claim was discontinued by Mr E's solicitors.

## LEARNING POINTS

- Rupture of the Achilles tendon can be seen in sports such as squash, football and running, but can also occur as a result of missing a step when walking and a subsequent abrupt landing.
- Prompt diagnosis of Achilles rupture is very important. A delay in treatment can lead to poorer outcomes, since a discontinuous or lengthened tendon can cause weak plantar flexion. The patient can be left with a limp and difficulty running, heel rising and stair climbing. More complicated surgery, with longer scars and higher risks of complications, may be needed, and return to sports may not always be possible.<sup>1</sup>
- Examination details, including negative findings, should be clearly documented.
- Achilles tendon rupture can be missed by non-specialists in about 20% of cases. It can be missed for multiple reasons that clinicians should be mindful of.<sup>1,2</sup>

## REFERENCES

1. Singh D, Acute Achilles tendon rupture, *BMJ* 351: h4722 (2015)
2. <https://cks.nice.org.uk/achilles-tendinopathy>



©jan-otto/gettyimages.co.uk

# A missed diagnosis but **no negligence**



BY DR ELLEN WELCH, GP

**M**s M, 42 years old, presented recurrently to her GP with widespread pruritis over her entire body and scalp. A reasonable period of topical treatments in primary care failed to improve her symptoms and she was referred to a consultant dermatologist, Dr H.

Dr H reviewed Ms M on four occasions over the following six months. During each consultation, a specialist nurse was present who watched Dr H carry out a detailed full body examination on Ms M, using magnification with a dermatoscope to visualise her skin lesions.

Dr H found no evidence of scabies infestation on examination, and reached a diagnosis of a prurigo-type eczema with a possible underlying contact dermatitis. Histopathological examination of Ms M's skin biopsy also confirmed a diagnosis of nodular prurigo. She was prescribed a potent topical steroid and oral prednisolone, which produced some symptomatic improvement.



## Ms M sought a second dermatology opinion and was diagnosed with scabies following the identification of what appeared to be a burrow

Unhappy with the lack of a complete resolution of her symptoms, Ms M sought a second dermatology opinion and was diagnosed with scabies following the identification of what appeared to be a burrow. She was given antiscabetic treatment, with no sustained response, and subsequently required further prednisolone, PUVA treatment and eventually dapsons to control her symptoms. Dapsons is a sulphonamide antibiotic, used to treat a variety of skin conditions unresponsive to first line therapy. It requires careful laboratory monitoring to avoid anaemia, and would not be used as a treatment for scabies.

Ms M made a claim against Dr H, complaining that she had failed to recognise that her symptoms were due to scabies, and that Dr H had failed to perform any diagnostic tests such as skin scrapings to establish the diagnosis. Ms M claimed that the failure to diagnose scabies caused her months of itching, scratching and pain before she received the correct treatment, and that the delay had led to the development of nodular

prurigo, scarring, and severe psychological trauma.

### EXPERT OPINION

An expert dermatologist reviewed the case records and found that Dr H's practice was in accordance with that of a responsible body of dermatologists. It was concluded that Dr H conducted a diligent search for the scabies mite using a dermatoscope, but that no lesions were present on which to base a diagnosis.

The expert explained that the diagnosis of scabies is based on the visual appearance of the burrow track or of the parasite itself, and skin scrapings were not necessary. In his opinion, if burrows were not found after such a detailed examination, witnessed by a nurse, it was unlikely any scabies were present at that time. He remarked that the distribution of Ms M's rash was also completely outside the normal pattern of scabies, as it involved the scalp and ears and the symptoms recurred after a transient response to antiscabetic medication – requiring further treatments and eventually dapsons for long term suppression.

Furthermore, the expert noted that Ms M's partner had remained rash and symptom free throughout the two years Ms M had been suffering with these symptoms, and if she had indeed had scabies, then he would have expected her partner to have been also infected. He supported as reasonable Dr H's diagnosis of severe widespread eczema complicated by nodular prurigo, which was confirmed on histological examination of a skin biopsy.

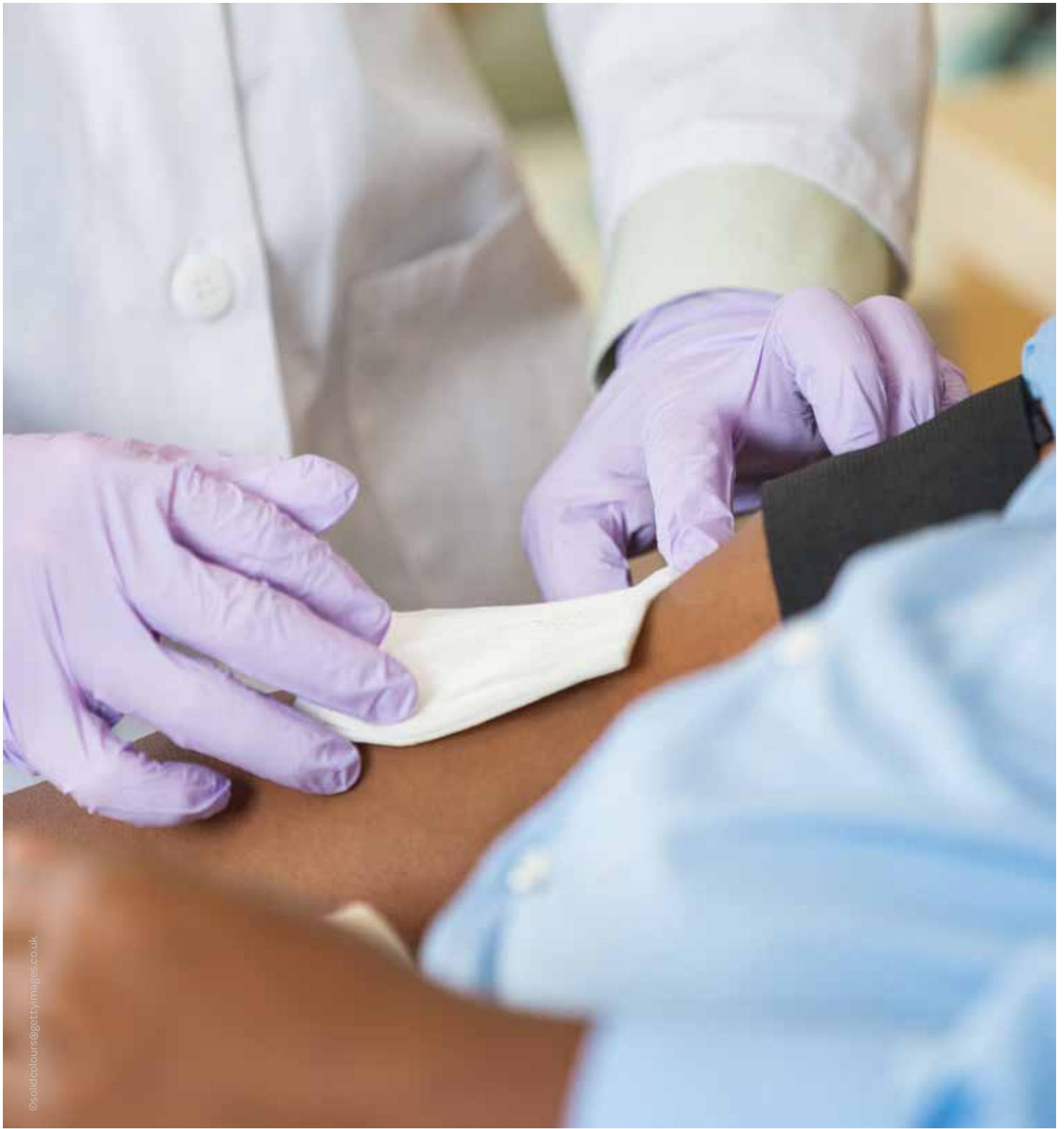
However, the expert went on to comment that Ms M's widespread excoriations could have destroyed any evidence of scabies infestation, and that the potent topical steroids and oral steroids she was reasonably prescribed could have over time exacerbated an infestation of scabies, enabling the dermatologist who provided the second opinion to detect a scabetic lesion.

In conclusion, it was considered that Ms M suffered from long-term severe eczema with, at times, seborrheic features and nodular prurigo verified by biopsy. There was suspicion but no proof that scabies may have been present at some point, and the clinical course of the condition was within the range of that expected in severe eczema. If scabies was present, it was mixed in with a severe to gross degree of eczema/dermatitis and nodular prurigo.

The claim against Dr H was subsequently discontinued.

### LEARNING POINTS

- Scabies is an itchy skin condition caused by *Sarcoptes scabiei*, a tiny burrowing mite. The word scabies comes from the Latin scabere, to scratch. One of the first symptoms is intense itching, especially at night. Management involves the application of topical antiscabetic treatment to all areas of the body for both the patient and household members and sexual contacts, together with decontamination of bedding, clothing and towels.
- From a medicolegal perspective, there is no breach of duty if practice does not fall below a reasonable standard; it is thus possible to miss a diagnosis of scabies without negligence if, as in this case, a patient is examined thoroughly and carefully with a view to the possibility of scabies being present, but no diagnostic lesions are found.
- In this particular case, there were a number of strong factual points that supported the absence of scabies at the time the Ms M attended Dr H, which once again highlights the importance of detailed medical record-keeping with every consultation.



©solidcolours@gettyimages.co.uk

# No renal review



BY DR ELLEN WELCH, GP



**M**r J, a 63-year-old gardener, visited Dr C for his annual health check and routine bloods were requested. Dr A, another GP in the surgery, reviewed the results and noted that Mr J had moderate renal impairment, with an eGFR of 59 ml/min/1.73m<sup>2</sup> and he coded Mr J as having chronic kidney disease stage 3.

The laboratory recommended that the blood test should be repeated within the next five days. Dr A assumed that Dr C would follow his patient up since he was the doctor who requested the initial blood tests.

A week later, Mr J was seen again by Dr C. He had a sore finger after pruning some trees, and this was the focus of the consultation. The blood results were not discussed and a repeat test was not mentioned as Dr C assumed that Dr A, as the doctor who reviewed the blood results, would have arranged subsequent testing and follow up.

Six months later, Mr J had an appointment with Dr A regarding his painful osteoarthritis. Naproxen was prescribed and placed on repeat prescription. The patient's previous blood results were overlooked and a repeat renal function was not requested.

Another year passed and Mr J consulted this time with an episode of diarrhoea and vomiting. Bloods were checked and showed an eGFR of 50 ml/min/1.73m<sup>2</sup>. The result was recorded by the duty doctor as being consistent with moderate renal impairment, but no further action was taken.

Mr J continued to receive naproxen on repeat prescription for a further two years, and during this time had documented medication reviews by both Dr A and Dr C. He was then reviewed by a locum doctor at the surgery, who noted a degree of renal impairment and stopped the naproxen. Blood tests had not been carried out for a two-year period, so the locum requested a renal function test, which showed a deteriorating eGFR of 44 ml/min/1.73m<sup>2</sup>. Mr J was referred to the nephrology team for review, and his renal function gradually improved after the naproxen was discontinued.

A claim was brought against Dr C and Dr A for continuing to prescribe naproxen despite evidence of renal impairment, and for failing to monitor Mr J's renal function, which had an adverse impact on Mr J's prognosis.



*Blood tests had not been carried out for a two-year period, so the locum requested a renal function test, which showed a deteriorating eGFR of 44 ml/min/1.73m<sup>2</sup>*

### EXPERT OPINION

Medical Protection investigated the claim and instructed experts in general practice and nephrology. The GP expert reviewing this case criticised the failure of both doctors to initially recheck Mr J's renal function in order to confirm or refute a diagnosis of chronic kidney disease. He noted several missed opportunities to act on the abnormal blood results, and was critical of the GPs for prescribing naproxen on a repeat basis without checking Mr J's renal function initially and at least on an annual basis.

The expert nephrologist considered that although the continued prescription of naproxen was likely to have contributed to Mr J's deterioration in renal function, most of the kidney damage occurred prior to the medication being commenced. He agreed that Mr J should have undergone further investigation after the second eGFR result showed a deterioration, and felt it was likely that the naproxen would have been withdrawn at this point. He felt the naproxen was unlikely to have had a clinically significant effect on Mr J's long-term prognosis.

### OUTCOME

On the basis of the nephrologist's report, a letter of response was served, admitting there were missed opportunities to repeat Mr J's blood tests, but denying that this resulted in a clinically significant difference to his renal function. The claim was subsequently discontinued.

### LEARNING POINTS

- Safety nets should be in place to ensure abnormal blood results are appropriately followed up – at both a practice and individual level. GP surgeries differ in their approach to following up results, but the requesting and reviewing clinicians should know where their own responsibilities lie. In this situation, both Dr A and Dr C assumed the other was managing Mr J with respect to his renal function, as a result of which his follow up was missed.
- A patient who is known or suspected to have chronic kidney disease should be monitored and managed according to relevant guidelines. At the time of this case the guidelines in place were NICE CG73 Chronic kidney disease: Early identification and management of chronic kidney disease in adults in primary and secondary care [2008]. This has subsequently been replaced by NICE CG182 Chronic kidney disease in adults: assessment and management [2014].
- Patients taking potentially nephrotoxic medication on a long-term basis should be regularly reviewed and consideration should be given to the need to monitor renal function. Electronic records allow this to be done at a practice level, by conducting clinical audits of all patients coded with chronic kidney disease to ensure they are managed appropriately.



# Failure to act on lower back pain



BY DR ANNA **FOX**, GP



BY DR ELLEN **WELCH**, GP

**M**r D was a 33-year-old motor mechanic. He was finding it difficult to work because of pain in his lower back and pains shooting down the backs of both legs; this puzzled him, as he had not done anything to injure his back. Mr D was also constipated, which was very unusual for him, so he made an appointment with his GP, Dr P, who examined his spine and found no localised tenderness. She observed his gait and noted that it was normal. Dr P prescribed tramadol on the basis that Mr D had tried it before to good effect, and she advised him to return if his symptoms did not settle.

Mr D's back pain improved slightly on tramadol but it did not go away. Seven months later, Mr D started to have problems passing urine. He didn't feel like he was emptying his bladder properly and he had to keep returning to the bathroom to try again. He went back to see Dr P, complaining of the lower back pain and the urinary issues. Dr P did not examine him, but arranged an MRI scan of his lumbar spine. The MRI report was suggestive of an arteriovenous malformation (AVM) in the lower thoracic and upper lumbar region.

It was almost a month later before Dr P wrote to the neurosurgical team with a copy of the MRI report. There was a further delay of approximately six weeks before Mr D underwent embolisation of the AVM.

Mr D brought a claim against Dr P. It was alleged that Dr P had failed to carry out an adequate neurological examination, failed to refer for a neurosurgical opinion in a timely manner and failed to act promptly on the MRI scan results. It was claimed that these delays had resulted in chronic bladder, bowel and sexual dysfunction. Mr D complained of

## “ ”

### *The MRI report was suggestive of an arteriovenous malformation (AVM) in the lower thoracic and upper lumbar region.*

ongoing neuropathic pain and weakness in his legs, rendering him unable to walk. He claimed that he could no longer work or drive.

#### EXPERT OPINION

Medical Protection instructed an expert GP to comment on the care provided by Dr P. The GP expert was critical of Dr P, stating that she should have taken a full history and examined Mr D during both consultations, with a view to assessing his neurological status. The expert felt that she should have considered the possibility of a spinal neurological problem at the second consultation, in light of Mr D's urinary symptoms. In addition, criticism was made of the failure to make inquiries or act on the MRI result in a timely manner. In light of the symptoms, the expert felt that the MRI results should have been discussed with a neurosurgeon the same day, which would have enabled their urgent assessment.

Medical Protection also instructed a consultant neurosurgeon to comment on whether the delays had caused or contributed to Mr D's injuries. It was felt that causation

was not clear cut. The neurosurgeon commented that even if a referral had been made following the second consultation, treatment may not have been provided materially sooner than it was; it followed from this that some of the neurological deficit may have occurred in any event.

Based on the expert advice, a decision was made to explore settlement.

#### FURTHER INVESTIGATION AND OUTCOME

Mr D was claiming a substantial amount of compensation to cover loss of earnings, costs of care and alternative accommodation adapted to his needs. Medical Protection noted that there were certain aspects of Mr D's claim that did not ring true. The medical evidence served in support of his claim contained a number of inconsistencies in his symptoms, particularly in relation to the loss of power in his legs. He had also declined examination by the spinal rehabilitation expert instructed by Medical Protection to assess his condition.

Medical Protection commissioned surveillance evidence to be gathered on Mr D. This demonstrated that he was fully mobile on both legs and did not need the assistance of crutches or a wheelchair. He was also able to drive. The surveillance evidence was disclosed to Mr D's solicitors with a request that he undergo electromyography testing to establish the extent of his neurological disability. This offer was not taken up; however, it allowed negotiation and settlement at a fraction of the amount originally claimed.

#### REFERENCES

1. [https://emedicine.medscape.com/article/248456-overview#a7Vascular Malformations of the Spinal Cord](https://emedicine.medscape.com/article/248456-overview#a7Vascular_Malformations_of_the_Spinal_Cord)
2. <https://cks.nice.org.uk/sciatica-lumbar-radikulopathy#diagnosis:sub:1>

**M** r X, a 25-year-old fit and active man, was reviewed by his GP, Dr A, with a recurrence of lower back pain. He had noticed lumbar back pain intermittently throughout his 20s, but played a lot of sports to which he attributed his symptoms. On this occasion, he described lumbar back pain radiating into both thighs, along with cramping in both feet. He had no other worrying features, so a repeat prescription for his usual analgesia was given.

Six months later, he returned to see Dr A, this time complaining of difficulty passing urine. Mr X recalled telling Dr A about his ongoing back problems, but this was not documented and Dr A did not recollect any back pain being mentioned. A urinalysis was negative and Mr X was given antibiotics for a presumed urinary tract infection.

Two months later, Mr X collapsed whilst playing football, complaining of a sudden onset headache. He was admitted under the care of Mr B's neurosurgical team and assessed by the locum doctor on duty. His head CT was unremarkable so a lumbar puncture was carried out, which showed blood in his CSF. The locum diagnosed a migraine. While in hospital, Mr X went into urinary retention and required catheterisation. The patient decided to discharge himself and left the hospital with the catheter still in situ, removing it himself at home the following day.

His symptoms persisted and, a week later, Mr X returned to the GP surgery to consult again with Dr A. He complained this time of both lumbar back pain and difficulty passing urine, which prompted Dr A to arrange an urgent MRI scan of his lumbar spine. This was carried out two weeks later and revealed an arterio-venous malformation (AVM) in the lumbar region, with a normal spinal cord and no evidence of nerve root compression.

Dr A wrote to Mr B to advise him of the MRI result, and Mr X was seen in the outpatient clinic three weeks later, by which time he had saddle anaesthesia and numb, weak legs, and was incontinent of urine and faeces. He underwent embolisation of his AVM, but unfortunately his symptoms did not resolve.

Mr X made a claim against both Dr A and the hospital.



## Case 2

### EXPERT OPINION

Expert opinion was critical of all involved in the case. The hospital breached their duty of care by failing to suspect, detect and treat the spinal pathology during the hospital admission. The GP experts agreed that Dr A had failed to diagnose bilateral sciatica when Mr X first presented. They agreed that bilateral sciatica is a red flag symptom that warrants urgent referral to the back clinic. They criticised Dr A's failure to document a physical examination, including straight leg raise and neurological testing.

Dr A and Mr X had different recollections of what was discussed during the second presentation at the surgery. The GP experts agreed that regardless of whether or not Mr X mentioned his back pain, Dr A should have explored potential neurological causes for Mr X's urinary symptoms, including specific enquiries regarding the back pain he mentioned in the previous consultation. Furthermore, they agreed that it is unusual for a UTI to be present with a negative urine dip test, and they criticised Dr A's failure to recognise urinary retention with back pain, and admit Mr X to hospital that same day to exclude cauda equina syndrome.

Once the AVM had been discovered on the MRI ordered by Dr A, the consensus among the experts was that the GP should have urgently sought the advice of a neurosurgeon, rather than leaving Mr X a further three weeks to have an outpatient appointment.

The experts conceded that on the balance of probability, there would have been no neurological findings the first two occasions Mr X consulted Dr A. It was also agreed that, had the AVM been detected and treated before Mr X collapsed, or even during his hospital admission, it is likely that he would not have been left with persisting neurological deficits.

### OUTCOME

The case was settled for a high sum, with a 25% contribution from Medical Protection on behalf of Dr A.

### REFERENCES

1. <https://emedicine.medscape.com/article/248456-overview#a7> Vascular Malformations of the Spinal Cord
2. <https://cks.nice.org.uk/sciatica-lumbar-radiculopathy#!diagnosisissub:1>

### LEARNING POINTS

- Spinal vascular malformations consist of an abnormal connection between the normal arterial and venous pathways. These malformations do not benefit from intervening capillaries. As a result, venous pressure increases and the individual is predisposed to ischemia or haemorrhage and then neurological compromise.<sup>1</sup>
- Spinal vascular malformations are a recognised cause of cauda equina. Missed cauda equina syndrome comes up again and again in *Casebook*. Early diagnosis and timely treatment are imperative if patients are to achieve optimal neurological outcomes.
- When assessing patients with back pain, clinicians should consider red flag symptoms and signs that may suggest a serious underlying cause. If found, urgent admission or referral for specialist assessment should be made. A recent NICE CKS details the red flags that clinicians should be aware of.<sup>2</sup>
- Think twice before attributing urinary symptoms to infection where presentation is atypical. Even when there is urine dip evidence of infection, consider that infection can co-exist with retention and specifically enquire about the presence of other neurological symptoms.
- Unfortunately, we can't always rely on our colleagues to have done the right thing. If a patient presents with concerning symptoms that persist after specialist investigations, take any action necessary to ensure the patient is reassessed with the appropriate degree of urgency.
- Medical Protection rarely carries out surveillance on claimants. In Case 1 however, it was considered appropriate because of the extremely high value claim and discrepancies that cast a doubt on the veracity of the claimant's case. Such evidence proved highly effective in dramatically reducing the size of Mr D's claim. This in turn saved Medical Protection – and members – a considerable amount of money, which could be better utilised elsewhere.



# A nitrofurantoin problem



BY DR ANNA FOX, GP

**M**rs A was a 70-year-old retired teacher. She had struggled with recurrent urinary tract infections for many years so her GP, Dr G, decided to start her on prophylactic antibiotics. He prescribed nitrofurantoin 50mg once daily, which worked well for her.

Mrs A had her liver function tests checked approximately 14 months after starting the nitrofurantoin and they were normal. Subsequent testing ten months later revealed a slightly raised ALT of 54. Dr G considered the results and decided that no further action was required. He knew that Mrs A was overweight and thought the slightly raised ALT was probably due to a fatty liver.

Five months later, now three years after the initiation of nitrofurantoin, Mrs A went to see her GP with a rash on her legs. It was unlike any rash she had had before and looked like lots of small bruises. Dr G was not sure what was causing the rash so he arranged some blood tests and referred her to hospital.

Liver function tests revealed a significantly raised ALT of 161. The rash was diagnosed as possible leucocytoclastic vasculitis. It was suggested that the rash and the raised liver enzymes were caused by the nitrofurantoin. The drug was stopped, Mrs A's rash resolved and her ALT returned to normal.

Mrs A brought a claim against Dr G, alleging a failure to perform medication reviews, a failure to arrange repeat testing when the ALT was noted to be mildly abnormal, and a failure to stop nitrofurantoin at an earlier stage.

## EXPERT OPINION

Medical Protection sought expert opinion from a GP and a rheumatologist. The expert GP was critical of Dr G for failing to repeat the liver function tests following the initial, slightly abnormal result. It was felt that Dr G should have considered other possible causes for the raised ALT, including nitrofurantoin, and not simply assumed it was due to a fatty liver. Had this been done, it is likely that nitrofurantoin would have been stopped approximately one year earlier than it actually was.

The rheumatologist's opinion was that Mrs A's raised liver enzymes and rash would be consistent with the use of nitrofurantoin, and on the balance of probability would not have occurred had the drug been stopped an earlier stage.

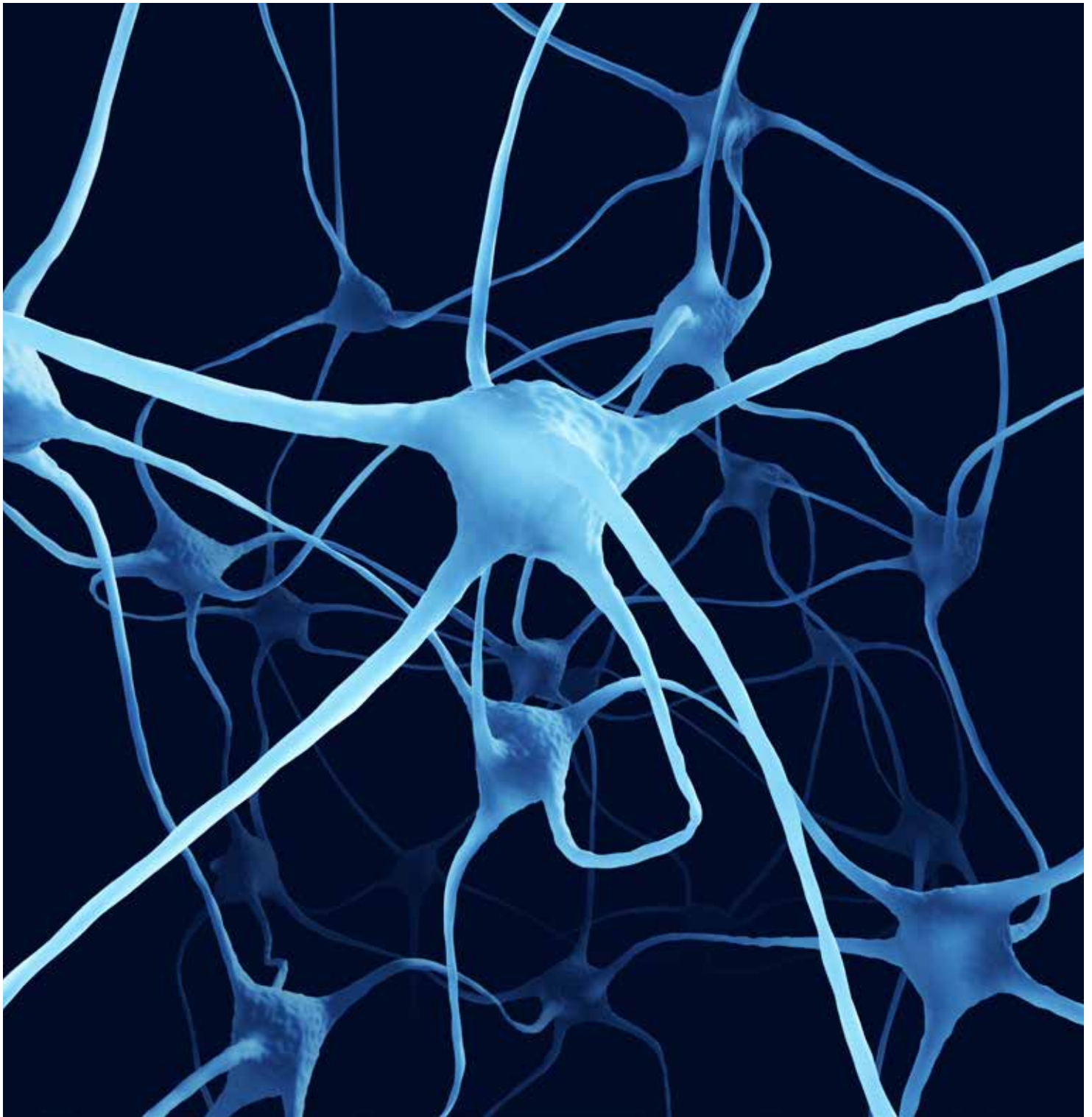
Based on the critical expert opinion, the case was deemed indefensible and was settled for a low sum.

## LEARNING POINTS

- **Hepatotoxicity is a potentially serious side effect of a number of drugs including nitrofurantoin. Clinicians should weigh up the risks and benefits of nitrofurantoin before initiating treatment, especially with long-term use in high risk patients.<sup>1</sup>**
- **Annual medication reviews provide an opportunity to assess the need for any monitoring and to determine what, if any, action needs to be taken regarding a specific drug. It is important to have robust systems in place to ensure that annual medication reviews are performed, particularly in patients on long term medication.**

## REFERENCES

1. Nitrofurantoin-induced hepatotoxicity: a rare yet serious complication, Sakaan SA, Twilla JD, Utery JB, Winton JC, Self TH, *South Med J* 107(2): 107-13 (2014)



# Sciatic nerve injury but was it negligent?



BY DR ELLEN WELCH, GP

**M**rs D, a 68-year-old housewife, had consulted her GP, Dr L, regularly over a number of years for various minor musculoskeletal complaints. She complained intermittently of low back pain, for which she typically received an intramuscular injection of diclofenac. Over a five-year period, it was documented that she had received five intramuscular injections from Dr L without any problems.

On one occasion, Mrs D visited Dr L complaining of severe dizziness, vomiting and headache. Dr L diagnosed her with likely vestibular neuronitis and offered her an intramuscular injection of dimenhydrinate to improve her symptoms. Dr L carried out the procedure as he had many times before, by asking Mrs D to lie in the left lateral position. He injected 1ml of the antihistamine into the dorsogluteal site at the upper, outer quadrant of her right buttock. She did not complain of any excessive pain following the injection.

Almost two weeks later, Mrs D returned to see Dr L, complaining of swelling at the injection site, associated with pain and numbness over her right leg. She reported that these symptoms had started soon after leaving Dr L's clinic, and she had continued to experience pain and numbness extending from the injection site, all the way down the lateral aspect of her right leg to her toes. Dr L explained that the pain could be caused by chemical irritation from the injected medication, and he prescribed anti-inflammatories.

Mrs D continued to experience these symptoms and consulted with Dr L several times. A month later, she decided to seek a second opinion from another GP, Dr U, who raised the possibility that she had sustained an injury of the right sciatic nerve due to the injection she had received. He referred her to see Dr P, an orthopaedic surgeon, who reviewed her in the outpatient clinic a month later. Dr P examined Mrs D and documented good range of motion in her hip, with no muscle wasting, normal power and normal lower limb reflexes. Diffuse numbness was found from the groin to the toes, which did not correspond to the distribution of any known spinal nerve root or peripheral nerve. Dr P reported that in his opinion, her condition was unlikely to be caused by any injury to the sciatic nerve, and she was treated for lumbar spondylosis.

Mrs D continued to consult with Dr L for another four months with persisting symptoms, and the clinical findings remained unchanged. He referred her for a neurological opinion, documenting in his referral notes that she was experiencing "numbness after injection three months ago with upper thigh muscle atrophy".



## *After his initial consultations with Mrs D, Dr L continued to consult with her on several occasions, but did not write down any of his physical examination findings*

Mrs D made a claim against Dr L, alleging iatrogenic nerve damage.

### **EXPERT OPINION**

As part of the neurologist's investigation, Mrs D underwent an electrophysiological study, which showed a slight reduced recruitment ratio over her right inferior gluteal nerve suggestive of chronic denervation.

Expert witnesses on both sides agreed that the results of this study could not fully account for Mrs D's clinical symptoms, since the inferior gluteal nerve is a purely motor nerve and would therefore not cause sensory symptoms. Her diffuse numbness did not correspond to the distribution of any known spinal or peripheral nerve.

Concerns were raised by the expert witnesses regarding Dr L's documentation of the case. After his initial consultations with Mrs D, Dr L continued to consult with her on several occasions, but did not write down any of his physical examination findings. He documented that she complained of 'muscle atrophy', but this was not confirmed on examination. Dr L stated that he wrote the words 'muscle atrophy' because these were the words Mrs D had used, and the problem

she complained of, but he himself did not find any objective evidence of atrophy.


However, neither the distribution nor the timing of the onset of Mrs D's symptoms fit the typical distribution for sciatic nerve injury, and there was no other documented neurological abnormality. Medical Protection served a letter of response denying liability, and the claim against Dr L was discontinued.

### **LEARNING POINTS**

- The dorsogluteal site or the 'upper, outer, quadrant' is the traditional IM injection site of choice, but it has been associated with injury to the sciatic nerve. The ventrogluteal region is now preferred as the first choice injection site despite having a shallower muscle depth as it is farther from neurovascular structures.
- Good clinical documentation, as always, is an essential part of the consultation, and should a patient take legal action, a defence will be built on the clinical notes. It is easy to become relaxed about documentation with patients who present often and/or are well known to the doctor, but examination findings, including significant negatives, should always be recorded.

### **REFERENCES**

1. Mishra P, Stringer MD, Sciatic nerve injury from intramuscular injection: a persistent and global problem, *The International Journal of Clinical Practice* 64, 11, 1573-1579 (2010)
2. Greenway K, Using the ventrogluteal site for intramuscular injection, *Nursing Standard* 18, 25, 39-42 (2004)
3. Coskum, H, Kilic C, Senture C, The evaluation of dorsogluteal and ventrogluteal injection sites: a cadaver study, *Journal of Clinical Nursing* 25, 1112-1119 (2016)



©Uruponggettyimages.co.uk

# Strong record-keeping – strong defence



BY MR SAM **DRESNER**, GENERAL SURGEON



**M**s Q, 58 years old, consulted Dr G, a gastroenterologist, with a history of dyspepsia, early satiety and altered bowel habit. Clinical examination, including digital rectal examination, was recorded as normal.

Dr G requested a full set of routine bloods and a chest x-ray (Ms Q had a long history of asthma), all of which were normal. Ms Q was advised that an upper gastrointestinal endoscopy and colonoscopy were required to further investigate the cause of her symptoms. Dr G documented that he had discussed the nature of the investigations, the possible need to take biopsies or remove polyps for histopathological examination and the risks involved. He provided standard hospital information booklets about the endoscopic procedures and obtained written consent from Ms Q. Specifically, he advised her that there was a very small risk of perforation (of the order of less than 0.01% for an upper gastrointestinal endoscopy and 0.1–0.5% for a colonoscopy), which might require emergency surgery.

Dr G provided Ms Q with bowel preparation and scheduled her appointment for a bidirectional endoscopy a few days later. When she attended for the investigations, Dr G reviewed her again in the presence of an endoscopy nurse. He went over the procedures once more and the risks involved, and obtained further written confirmation of her consent.

The hospital records indicate that the patient entered the endoscopy room at 12pm and was provided with conscious sedation using intravenous midazolam and fentanyl. Her blood pressure was recorded as 130/60, oxygen was supplied via nasal cannula and her saturations noted as >98% throughout the procedure. The initial upper gastrointestinal endoscopy demonstrated some mild antral gastritis but no other abnormalities. A helicobacter pylori test was negative.

Antral biopsies were taken, which later confirmed acute-on-chronic gastritis and intestinal metaplasia. Attention then turned to the colonoscopy. Dr G recorded that the colonoscope was inserted up to 25cm, where extensive diverticular disease was evident. Dr G encountered difficulty in negotiating this segment of the colon, noting diminished insufflation and that Ms Q was experiencing pain. A colonic perforation was suspected, and the procedure was therefore immediately abandoned.

Dr G noted that Ms Q's abdomen was distended, with lower abdominal tenderness but no peritonism. He prescribed broad spectrum intravenous antibiotics, intravenous fluids and more opiate analgesia, and advised that she should be kept 'nil by mouth'. Ms Q

remained stable and was transferred directly to the radiology department for an urgent CT scan of the abdomen and pelvis, and afterwards was moved to a ward at 1.05pm.

Dr G attended Ms Q at 1.40pm and informed her and her relatives that a perforation of the colon had been identified on the CT scan, with extensive retroperitoneal gas but also some possible intraperitoneal free gas and fluid. By this stage Ms Q's abdomen had become more distended, her pain was worse and she had a tachycardia >100bpm. Dr G advised that in view of her clinical deterioration and the CT findings, surgery would probably be required. After discussion with Ms Q and her relatives, he arranged transfer to a nearby emergency hospital facility.

Dr G contacted the on-call surgical team at the nearby hospital, prepared a referral letter and escorted the patient during her transfer, briefing the receiving staff on her condition upon arrival. Emergency surgery was performed later that day with resection of the perforated diverticular segment and primary anastomosis. Dr G contacted the surgeon the following morning, who confirmed that the prompt action had minimised the contamination seen in the abdominal cavity at the time of surgery, allowing him to perform a primary anastomosis. Dr G visited the patient several times during her admission and subsequently saw her in his clinic for review after discharge, noting that she had made a full recovery.

Three years later just before the end of the limitation period for bringing a claim, Ms Q decided to pursue a claim against Dr G.

### EXPERT OPINION

It was clear from the detailed documentation that Dr G provided to his Medical Protection legal team that he had acted entirely appropriately in response to a well-recognised but rare complication. Ms Q had been clearly warned about and understood the risks prior to the procedure. As a result, expert advice for Medical Protection concluded that the patient's solicitors were unlikely to pursue their claim and, indeed, the case was subsequently dropped.

However, Ms Q went on to complain about Dr G to his Medical Council. Medical Protection again assisted Dr G by providing further reassurance and advice, confirming that their independent expert opinion felt his actions had been entirely appropriate. They helped him compile an appropriate response to the investigation, which demonstrated reflection and insight but robustly defended his communication with the patient and the subsequent handling of this well recognised complication. The complaint was dismissed without further action.

## LEARNING POINTS

- Accurate and clear documentation, which often may need to be relied upon years after the event, are the cornerstone of any medicolegal defence. In this case, there was a thorough process of consent, recording the risks of the colonoscopy and the potential consequences of any complications. When it became apparent that a perforation had occurred, Dr Q was able to rely on his detailed notes, which confirmed his prompt and appropriate actions and his clear communication with the patient and her relatives.
- The development of a complication is not necessarily evidence of negligence, provided the patient has been warned of the risks, the procedure has been carried out to an acceptable standard and all reasonable steps have been taken to minimise the effects of the complication. In this case Dr Q's prompt and appropriate actions may have prevented further contamination of the abdomen and the severity of sepsis. Although ultimately this did not prevent a legal claim it helped contribute to a robust defence.
- This case also highlights the necessity to be open and honest when complications develop. All healthcare professionals have a professional responsibility to be honest with a patient when things go wrong: this was exemplified by Dr G's prompt and clearly documented communication with Ms Q and her relatives. This was not a medical mistake but a recognised complication about which Ms Q had been warned. Although Dr G's open and honest approach did not prevent the complaint to his Medical Council, it helped contribute to its dismissal as he was able to demonstrate that he had carried out professional duties promptly and appropriately.



## The age of information

I read with interest your case report on the pulmonary complications of nitrofurantoin.

Every prescription dispensed to me has always contained an information leaflet saying in bold: "Read all of this leaflet carefully before you start using this medicine." In this particular instance, the leaflet then goes on to say that the lungs may react to this drug causing breathlessness, "especially in elderly patients".

All the drugs I have ever received contain this type of information leaflet. This leaflet is clearly meant for the patient, and I assume its distribution is standard practice. Whatever the perceived failings of the doctor, does the patient not bear some responsibility in this age when patients can often arrive at the doctor with volumes of downloaded information?

**Gerald McEnery**  
Retired paediatrician

## Why no colonoscopy?

I am an inveterate reader of your journal, which I find most instructive not only from the medicolegal aspect but from a clinical perspective. Thus I find your article on bleeding haemorrhoids extremely puzzling and perplexing.

Firstly, the diagnosis is made on the history and rectal palpation. The history is excellent but a conclusive diagnosis cannot be made on the history alone. Rectal palpation also cannot suffice. A simple and conclusive examination is proctoscopy. Visualising the haemorrhoids is conclusive and, in the absence of such visualisation, irrespective of the age of the patient, colonoscopy is mandatory.

Secondly, colonoscopy would have revealed the cause of the bleeding and, at this stage, the tumour may well have been contained and thus totally curable. In other words, this young man may well have been alive and well today.

**Dr Leslie Hotz**

I was appalled when I read this case. I do not agree with the outcome and it is my opinion that the standard of care was very poor. Subsequently, this case is indefensible.

I cannot believe that a GP expert would defend this case by stating that the history of straining with fresh blood on defecation would be consistent with a diagnosis of haemorrhoids. The latter can also be consistent with the diagnosis of colorectal cancer. That is why you may never assume that rectal bleeding is due to haemorrhoids: this is a very basic rule that I was taught in medical school almost 30 years ago.

The patient had a six-month history of abdominal pain and rectal bleeding when he presented to his GP. He should have immediately



*These are interesting points. The amount of information you give to each patient will vary according to the nature of their condition, the potential risks and side effects and the patient's needs and wishes. You should check that the patient has understood the information, and encourage them to ask questions to clarify any concerns or uncertainty. Patient information leaflets are useful supplements to the information you give patients about their medicines, but they are not a substitute for that information.*

*In answer to your question, if a patient is already well informed about a particular drug from their online research the discussion can of course be tailored to their 'needs and wishes', but ultimately it is the responsibility of the doctor to ensure that the patient has been given (and has understood) the information they need to make a decision.*

been referred for further assessment – there is no excuse. The fact that Dr B felt that this was most likely haemorrhoids secondary to constipation is on its own also a reason for further investigation. Any adult with a change in bowel habits (without an obvious reason) should also be investigated further.

Students and young doctors should not be taught that this standard of care is acceptable by any means. We cannot condone what happened here. I feel that the GP expert in this case should be held liable.

**Dr Debbie Bekker**



*Thank you for your comments on the case report on haemorrhoids that appeared in the latest edition of Casebook.*

*I appreciate your concern, and should first of all clarify that the cases we publish are taken from around the world in the countries in which we support members, where local practices and guidelines may vary. Cases may also take a number of years to resolve, and so accepted best practice and guidelines can change in that time. In this case our member had asked the deceased to attend for blood tests and to return in four weeks for review. Had the bleeding been reported to be continuing, our member would have referred the deceased for further investigations in secondary care. This plan was clearly documented in the medical records.*

*The claim was successfully defended at an early stage in the litigation process on the basis of a supportive expert report, which was a good outcome for our member. However, we recognise that in reporting this case we should have taken the opportunity, as we usually do, to illustrate current good practice by reference to up-to-date guidelines.*

# Over to you

## Antibiotic allegations

In the last issue of *Casebook*, in the case “Antibiotic allegations”, patient G gave a history of cough and fever for four days and, in the next paragraph, it was recorded that she “was on day four of a five day course of amoxicillin prescribed by her dentist”. It seems that she did not see any connection between going to the dentist and her cough. Normally one does not go to a dentist for a viral respiratory infection, and a dentist usually prescribes amoxicillin for a dental procedure on an infected (or potentially infected) tooth condition. Could it be that her fever and cough started or deteriorated after the dental procedure? Could she have choked and aspirated some of the oral fluid during the procedure?

As a thoracic surgeon, I have seen quite a few cases of cough and fever following dental procedures, some developing into pneumonia, probably due to aspiration. These cases were confirmed by a CT scan and bronchoscopy. A bronchoscopy would help to confirm the diagnosis, identify the offending organism (which is often resistant to the penicillins including amoxicillin) and, by clearing the bronchus and starting the correct antibiotics, set the pace to recovery.

Perhaps we should look deep through the stories the patients try to tell us. Sometimes we need to view the various facts from another angle. Perhaps we should be more aggressive or defensive or thorough in our investigations. Our patients’ demand for perfection in medical service is ever-growing. Unless we can meet such challenges, our list of litigation will keep growing.

**John SM Leung MB, BS, FRCSEd**



*Thank you for your email regarding the case report “Antibiotic allegations”. Your observations on this case are interesting and identify common themes that we see arising from our cases, such as the need to take a detailed history, revisit a diagnosis when a patient does not improve, and carefully manage the expectations of patients.*

## Antibiotics: to complete or not?

I notice in your case entitled “Antibiotic allegations”, your expert comments: “Incomplete antibiotic courses promote the growing problem of antibiotic resistance.” However, my understanding is that the latest evidence has turned this old adage upside down, and suggests that completing courses of antibiotics may actually contribute to antibiotic resistance. I have been told by some senior colleagues that we ought to be advising patients to cease taking antibiotics when they become asymptomatic, rather than advise them to ‘complete the course’.

Are you able to get a microbiologist to comment on this? I would hate your fine publication to be encouraging inappropriate antibiotic stewardship.

**Dr David Jonathan Jones**



*I note your concerns about the case report “Antibiotic allegations”, specifically whether the advice from our expert that “incomplete antibiotic courses promote the growing problem of antibiotic resistance” may no longer be correct.*

*I have asked a microbiologist to comment on this, who has advised me that the recent debate on the subject of completing a course of antibiotics was initiated by an article in the BMJ in July 2017. There is apparently no new guidance for clinicians and the matter is still being debated among the experts.*

*We will keep an eye on developments in this area and bear this in mind for future case reports. Although the experts we instruct must provide their opinion on the standard of care according to accepted practice at the time of the incident giving rise to a claim, we also want to ensure that the advice given in *Casebook* is up to date.*



**We welcome all contributions to Over to you.  
We reserve the right to edit submissions.**



**Please address correspondence to:**

Casebook Editor, Medical Protection, Victoria House, 2  
Victoria Place, Leeds LS11 5AE, UK.  
Email: casebook@medicalprotection.org

# ONLINE LEARNING

## Anytime. Anywhere.

Support your career development with our online learning, which offers interactive modules that can be accessed at a time and place to suit you.

- Free to all members
- Interactive content produced for doctors by doctors
- Track your learning and download certificates in your personal account
- Accessible via desktop, tablet and mobile 24/7



Register now and start your online learning today

**VISIT**  
[prism.medicalprotection.org](https://prism.medicalprotection.org)