

Professional support and expert advice
from your leading medicolegal journal

CASEBOOK

VOLUME 27 | ISSUE 2 | NOVEMBER 2019

CARIBBEAN AND BERMUDA



The GP harassed by a patient

We assist when a patient stalks their former GP

PAGE 16-17

From the case files

MISSED CASE OF OVARIAN CANCER

We defend a radiologist at trial

A TROUBLESOME LUMP

Supporting a GP when a claim goes to trial

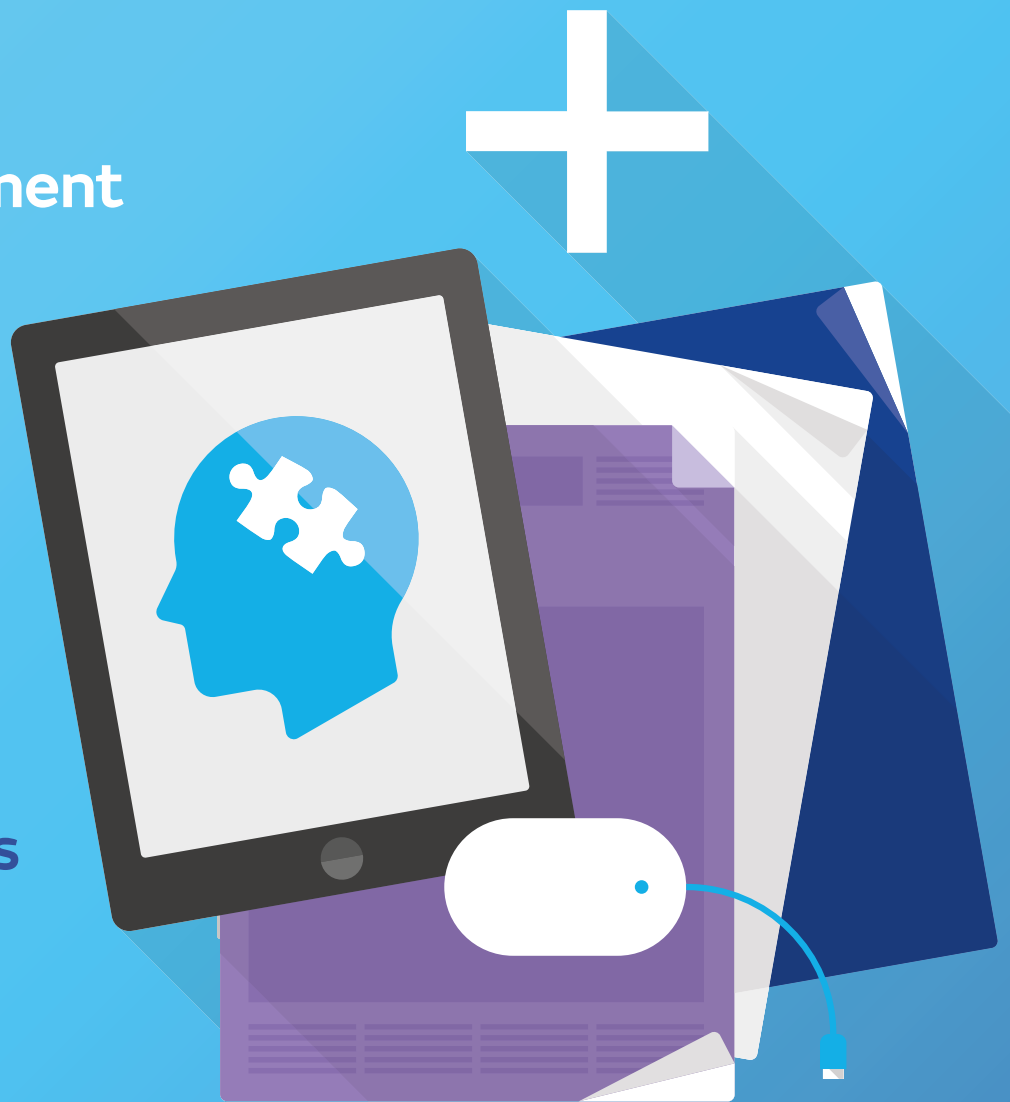DRUGS AND SEIZURE – MEDICAL COUNCIL HEARING

An investigation into Dr A's cocaine use

MAXIMISE YOUR MEMBERSHIP RISK MANAGEMENT... AT YOUR FINGERTIPS

- Risk Management Workshops
- Case Reports
- E-learning
- Factsheets

Free to members



VISIT TODAY
medicalprotection.org

What's inside...

Every issue



Welcome

Dr Marika Davies, Editor-in-Chief of Casebook, welcomes you to this edition and comments on some topical issues.



Over to you

What did you think about the last issue of Casebook? All comments and suggestions welcome.

Case reports



05

Spinal surgery blamed for worsening symptoms

A patient makes a claim following surgery for a herniated intervertebral disc. Initially her symptoms improved but later worsened – what happened next?



06

Fatal heart attack leads to multiple jeopardy

The death of a patient following the insertion of a temporary pacing wire leads to numerous issues for the cardiologist, including a police investigation and inquest. Find out how Medical Protection helped at each stage.



08

Drugs and seizure lead to Medical Council hearing

Specialty trainee Dr A takes illegal drugs and suffers a seizure. While he fully recovers, he faces a regulatory hearing over his conduct – the Medical Protection team assists.



10

A troublesome lump

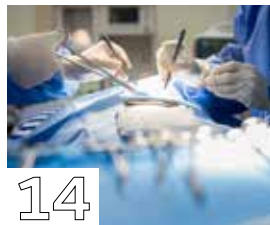A GP faces a claim following a patient's death – find out why he is criticised for allegedly not following local processes, and how Medical Protection defended the case to trial.



12

A rare diagnosis that seemed common

A patient is eventually diagnosed with a small bowel tumour but makes a claim that the diagnosis was delayed. The Medical Protection team assists in the case.



14

Could it be cauda equina?

A claim is made against a spinal surgeon and the hospital for alleged cauda equina syndrome following numerous procedures – it goes all the way to trial.



15

Missed case of ovarian cancer goes to trial

The alleged failure of a radiologist to spot signs of ovarian cancer leads to a claim. The case eventually goes to trial – but what was the outcome?



16

The GP harassed by a patient

A GP contacts Medical Protection for assistance with a patient who is stalking them. Find out how the team was able to help with this stressful situation.

Opinions expressed herein are those of the authors. Pictures should not be relied upon as accurate representations of clinical situations. © The Medical Protection Society Limited 2019. All rights are reserved.

ISSN 1366 4409

Casebook is designed and produced twice a year by the Communications Department of the Medical Protection Society (MPS). Regional editions of each issue are mailed to all MPS members worldwide.

The Medical Protection Society Limited ("MPS") is a company limited by guarantee registered in England with company number 00036142 at Level 19, The Shard, 32 London Bridge Street, London, SE1 9SG.

MPS is not an insurance company. All the benefits of membership of MPS are discretionary as set out in the Memorandum and Articles of Association. MPS® and Medical Protection® are registered trademarks.

Cover: @AlexLinch@gettyimages.co.uk

Casebook publishes medicolegal reports as an educational aid to Medical Protection members and to act as a risk management tool. The reports are based on issues arising in Medical Protection cases from around the world. Facts have been altered to preserve confidentiality.

Get the most from your membership...



Visit our website for publications, news, events and other information: medicalprotection.org



Follow our tweets at: @MPS_medical

Editorial team



DR MARIKA
DAVIES
EDITOR-IN-CHIEF



GARETH
GILLESPIE
EDITOR

Case report writers



DR JO
GALVIN



DR JAYNE
MOLODYNKI



DR HEIDI
MOUNSEY

PRODUCTION

Emma Senior Production
Conor Walsh Designer
Print Spellman Walker

Please address all correspondence to:

Casebook Editor, Medical Protection, Victoria House, 2 Victoria Place, Leeds LS11 5AE,
United Kingdom
casebook@medicalprotection.org

Welcome

DR MARIKA
DAVIES
EDITOR-IN-CHIEF



Looking back over the case reports we have published in *Casebook*, it is easy to focus solely on the clinical detail or the legal outcome of a case. But it is also important to remember that at the heart of each case is a doctor who has faced criticism or a sanction for an alleged error or adverse outcome, which is an incredibly stressful and often isolating experience for any doctor to go through.

Medical Protection members can be reassured by the fact that our in-house clinical and legal teams are made up of highly-qualified individuals who have accrued years of expertise in fields from across a wide variety of medicolegal matters. This means that whether you are facing a claim or investigation, a complaint or Medical Council hearing, a disciplinary with your employer, or an inquest into a patient's death – there is always an experienced, knowledgeable specialist in our ranks who can support you and handle the case with confidence and assurance.

As always with *Casebook*, we try to reflect this wide scope of assistance in our latest collection of case reports. In this edition you will find everything from claims that end up in court, inquests and police investigations, to calls for advice in dealing with some

practical workplace-related situations. While these cases often involve unpleasant developments and can be unsettling reading, members should take heart from the many encouraging outcomes for the clinicians involved, and the level of robust support provided by Medical Protection.

The case reports are also there to be used as valuable educational resources, with the numerous learning points on risk management that each author provides at the end of each report. You will also find advertised elsewhere in this publication more information on other risk prevention services available to you as a member, which can be found on our website medicalprotection.org.

I hope you enjoy this edition and please do continue to share your views on *Casebook* or any other issue with me, via casebook@medicalprotection.org.

Dr Marika Davies
Editor-in-Chief



Spinal surgery blamed for worsening symptoms



BY DR HEIDI MOUNSEY,
MEDICOLEGAL CONSULTANT,
MEDICAL PROTECTION

Miss L, a 39-year-old horse groom, had a long-standing history of low back pain, for which she had previously consulted a chiropractor. She attended her GP after experiencing a sudden worsening of pain along with saddle paraesthesia, bilateral leg numbness and urinary incontinence. Her GP was concerned about a possible diagnosis of cauda equina syndrome and referred Miss L to the emergency department.

A magnetic resonance imaging scan performed the same day showed a bulging intervertebral disc at L5/S1 and she was referred to the neurosurgical team who, following review of the images, recommended Miss L was discharged home with analgesia.

However, Miss L continued to experience significant back pain, now radiating down her left leg with ongoing paraesthesia to both buttocks and requested to be seen by a spinal surgeon on a private basis. She was therefore referred to Mr W, consultant spinal surgeon, and was reviewed several weeks following her discharge from hospital.

On examination, Mr W identified a reduction in lumbar flexion and a severely limited straight leg raise on the left side, with the right side being normal. Sensation was reduced to her left calf and foot, her right foot and both buttocks. Power to the left ankle was reduced but otherwise normal to the lower limbs. Miss L also complained of ongoing episodes of urinary incontinence.

Mr W reviewed the MRI scan from the hospital and considered this demonstrated disc degeneration at L4/5 and L5/S1, with a left sided disc protrusion at L5/S1 that was migrating centrally.

Mr W recommended surgery in the form of a posterior lumbar interbody fusion, cautioning Miss L that this may not relieve all of her pain and other symptoms, and was primarily intended to prevent further deterioration.

She was informed that there was a small risk surgery would make matters worse, and that an alternative option was to continue conservative management.

Miss L consented to surgery after considering her options, and this proceeded uneventfully.

A month following the surgery Mr W reviewed Miss L. Miss L reported that the back pain had resolved, her leg pain had lessened and, while her incontinence and numbness had not completely resolved, both were improved from the situation prior to surgery.

However, around a year later, Miss L once again developed back pain with worsening bladder dysfunction and numbness to her feet and buttocks, along with disturbance of bowel function, stating these symptoms to be worse than those she had experienced prior to her surgery. A further MRI scan was arranged, which did not demonstrate a cause for the symptoms.

Miss L brought a claim against both the hospital and Mr W, alleging the hospital failed to diagnose acute lumbosacral radiculopathy by means of a lumbar puncture and neurophysiological studies; that Mr W advised and performed unnecessary spinal surgery; and that both the hospital and Mr W should have prescribed a course of high dose oral steroids, which would have relieved her symptoms and prevented their recurrence. It was further alleged that the surgery was the cause of her worsened symptoms.

OUTCOME


The case was considered by Medical Protection to be complex, with a number of allegations against both the hospital and Mr W, and with Miss L's solicitors suggesting that the investigations and treatment that were performed would not normally be routinely carried out for such symptoms.

Opinion on Mr W's actions was sought from an expert spinal surgeon, who concluded that surgery was an appropriate course of action to offer under the circumstances; and that although Miss L continued to experience symptoms, her medical records indicated that she did experience improvement following the surgery, and there was no indication it caused harm.

On receipt of the expert report, the case was again fully reviewed by Medical Protection's medical and legal team, and it was considered that the case should be robustly defended. A barrister was therefore instructed to draft a formal defence on Mr W's behalf and, following receipt of this, Miss L's solicitors discontinued the claim.

LEARNING POINTS

- Comprehensive and clear documentation of any history and examination performed is vital should there be a later challenge to the diagnosis made at the time of the consultation.
- Risks and benefits of any surgical procedure offered, and the alternative options available (including the option of doing nothing), should be fully explained to ensure that decision-making and consent are informed.
- In an elective situation, time should be provided after the consultation and prior to scheduling surgery to allow the patient to weigh up the options and form a considered view as to whether or not they wish to proceed.



Fatal heart attack leads to multiple jeopardy



DR JO GALVIN, MEDICOLEGAL CONSULTANT, MEDICAL PROTECTION

Mr M, a 66-year-old man with a complicated medical history of poorly controlled insulin dependent diabetes, angina, hypertension and inflammatory arthritis, was admitted acutely with symptomatic bradycardia and hypotension secondary to complete heart block.

Dr F, a newly appointed consultant cardiologist, decided he required insertion of a temporary pacing wire. The procedure was technically difficult as Mr M found it difficult to lie flat and was intermittently agitated. The radiographer was relatively inexperienced and struggled to obtain clear images.

Two hours post-procedure Mr M suffered a cardiac arrest and, despite prompt resuscitation, he died.

A postmortem identified that the pacing wire had perforated the right ventricle and the tip lay in the pericardial space, which was filled with fresh blood.

Three weeks later, while Dr F was on holiday abroad, she was informed that the case had been passed to the police.

Deeply upset, Dr F contacted the Medical Protection advice line.



Attending a police interview is a very daunting experience for most healthcare professionals, and it is vital they have a solicitor who is experienced and familiar with the process to advise and support them

HOW MEDICAL PROTECTION HELPED

The Medical Protection advisory team liaised with the police officer dealing with the case, obtained a copy of Mr M's records, instructed a solicitor with extensive experience of dealing with such cases, and arranged to meet with Dr F on her return from leave. After the meeting the solicitor drafted a comprehensive statement on her behalf.

Medical Protection also instructed a cardiology expert who commented that it was a technically challenging case. She explained perforation of the ventricles is a recognised, but infrequent, complication and said that the suboptimal imaging contributed to the complication not being recognised more promptly.

WHAT HAPPENED NEXT?

Hospital investigation

Dr F had a meeting with the hospital, who offered her occupational health input and explained they were considering restricting her practice, such that she would not undertake any interventional procedures pending the outcome of the police investigation.

Aware this could take many months, the Medical Protection advisory team – with Dr F's agreement and with the support of her colleagues – advocated that she would not do on-calls and would have supervision for interventional procedures. This would ensure patient safety and avoid Dr F becoming deskilled. The hospital agreed it was a proportionate way forward.

The hospital conducted a serious incident (SI) investigation, which was critical of some of Dr F's actions but also accepted the imaging equipment was suboptimal.

Police investigation

A Medical Protection solicitor accompanied Dr F to the police interview, following which the case was put under consideration for prosecution. Ten months later, it was decided that no charges should be brought.

Inquest

Shortly after the case was closed by the police, the coroner listed the case for an inquest and Dr F was called as a witness to give evidence. The coroner returned a narrative conclusion, which identified where there were failings, and commented positively on Dr F's open and candid approach when giving evidence.

The family subsequently made a claim in negligence, which was settled by the hospital.

Six months later, Dr F returned to full independent practice.

LEARNING POINTS

- Seeking advice at an early stage is crucial. Medical Protection provides a 24-hour advice line for members to speak to a case adviser or medicolegal consultant. In this case, even though Dr F was abroad, the adviser was able to take immediate steps to assist Dr F.
- It is essential to have access to the contemporaneous records before providing a statement. By obtaining the records, Dr F was able to refresh her memory of the case and Medical Protection was able to instruct an expert.
- An early expert opinion can be invaluable in identifying the strengths and vulnerability of a member's position. In this case it gave Dr F an opportunity to consider the expert's view; while she did not agree entirely with it, she was accepting of the main criticisms.
- Attending a police interview is a very daunting experience for most healthcare professionals, and it is vital they have a solicitor who is experienced and familiar with the process to advise and support them. Medical Protection strongly advises members to use a solicitor instructed by us, who knows the professional ramifications and can provide advice on the other aspects of the case.
- Where concerns arise about a practitioner's capability, hospitals often consider if the practitioner's practice should be restricted. In some cases, the practitioner may be excluded from all duties. In this case the incident arose from a discrete aspect of Dr F's practice. She showed insight into how she should have acted differently and she was willing to accept supervision, so the hospital was reassured she could continue to practise safely.
- This was a very difficult and distressing time for Dr F, especially so early in her consultant career. The advice and guidance from the adviser and the solicitor helped her to cope with the various investigations.

Drugs and seizure lead to Medical Council hearing



DR JO GALVIN, MEDICOLEGAL CONSULTANT,
MEDICAL PROTECTION



Dr A, a specialty trainee, attended a music festival where he bought and took cocaine.

Shortly afterwards Dr A suffered a seizure and was taken to the emergency department of the local hospital. He was admitted overnight for observations. Dr A informed his clinical supervisor who asked him to come to see her before he returned to work and explained she would discuss the matter with the medical director.

Two days later, Dr A and his clinical supervisor attended a meeting with the medical director. At the meeting Dr A was informed that the hospital was immediately excluding him and requesting an urgent occupational health review. Dr A expressed deep regret for his actions and apologised for the disruption to the service that his actions had caused.

The medical director requested that he self-refer to the Medical Council and asked for confirmation he had done so within the next 48 hours.

Extremely upset, Dr A contacted Medical Protection for advice. The Medical Protection advisory team advised him that there was no absolute obligation to self-refer to the Medical Council, but in light of the medical director's direction it was advisable to do so promptly.

Medical Protection also advised Dr A to engage fully and openly with occupational health and suggested he consider seeing his own GP.

As the matter arose from Dr A's personal conduct, he was advised that assistance with his employer's investigation was not within the scope of the benefits of Medical Protection membership. He was advised it was likely he would receive correspondence from the Medical Council, however, and if so, to contact Medical Protection immediately so the issue of assistance could be considered.

Three days later Dr A called as he had received a letter from the Medical Council inviting him to attend a hearing five days later.

Medical Protection assisted Dr A with the Medical Council investigation and a Medical Protection solicitor was instructed.

At the hearing, the Medical Council solicitor recommended to the panel that conditions should be placed on Dr A's registration.

On Dr A's behalf, the Medical Protection solicitor submitted that imposing conditions on Dr A's registration would be premature and unnecessary. She highlighted that Dr A had shown insight in to his wrongdoing, been open and candid from the outset



Dr A expressed deep regret for his actions and apologised for the disruption to the service that his actions had caused

and complied fully and promptly with occupational health. She further submitted that Dr A was currently not practising clinically and that arrangements were in place for hair testing by occupational health. If the results of those tests were positive, the Medical Council could invite Dr A to a further hearing; imposing conditions while those tests were pending would be disproportionate.

The panel determined no order was necessary and the matter could be reconsidered when further information was available.

Shortly afterwards the results of Dr A's hair testing became available, which showed recent use of opiates but no evidence of prior usage.



The hospital convened a meeting with Dr A and they agreed he could resume clinical duties and would have regular meetings with his clinical supervisor to support his return to practise. Further unannounced hair testing was arranged by occupational health.

The Medical Council investigation of the case continued and Dr A attended two health assessments arranged with two Medical Council-appointed health assessors, who liaised with his GP and occupational health. They concluded he had no underlying addiction and that this was likely to be a one-off event.

Over the next eight months Dr A had two more negative hair tests. He reflected at length on what happened, discussed it in his appraisal and devoted time to teaching medical students and junior colleagues about the importance of ensuring their behaviour at all times reflects the standards of the profession.

At the conclusion of the Medical Council investigation, the Medical Council wrote to Dr A with a letter setting out the allegations in relation to his misconduct, and explained they were minded to conclude the case with a warning.

Dr A had a further meeting with Medical Protection to prepare a response. He was advised that a warning was potentially a proportionate outcome; however, given the extent of Dr A's remediation, it was decided that the response would propose the case could be concluded with a letter of advice.

A detailed response was drafted, supported by Dr A's reflections, feedback from his clinical supervisor, the teaching sessions he had undertaken and positive testimonials from medical students and colleagues.

OUTCOME

After an anxious wait, Dr A received a letter from the Medical Council advising him that the matter was concluded with a letter of advice. Two years on from this event, Dr A secured a consultant post in another hospital.

LEARNING POINTS

- It is important doctors are aware that their conduct outside their clinical work can have consequences for their professional life and their registration.
- Dr A's early contact with Medical Protection ensured that the team were able to advise him on the important step of a self-referral to the Medical Council. In this case it was inevitable the hospital would inform the Medical Council and it was preferable Dr A did so first.
- Being excluded from all duties can be a deeply isolating and difficult experience for any healthcare professional.
- Expert advice is essential when navigating Medical Council procedures. The suggestion that the case could be concluded with a letter of advice was a finely balanced and carefully considered decision, which was only possible with an in-depth knowledge of all aspects of the case.
- The preparation of a detailed response to the Medical Council was a pivotal point in the case as it was Dr A's opportunity to respond to the allegations, demonstrate insight into his actions and explain the steps he had taken to remediate.
- Demonstrating insight takes time and effort; it is a process that should be started as soon as possible.



Mr L, a 62-year-old retired accountant, presented to his GP surgery with a lump over his sternum, which had been present for approximately four weeks. Dr C considered the lump to be a small lipoma measuring 1cm x 1.5cm and advised Mr L to monitor it and to return if it changed.

After six weeks, Mr L returned to see Dr C, stating that the lump had increased in size and had been uncomfortable for the past day or two during heavy exercise. Dr C noted that the lump was now approximately 2cm x 2cm in size, but still clinically considered it to be a lipoma. Dr C advised Mr L to try a topical analgesic to relieve the discomfort and emphasised he should return for consideration of referral for excision if the discomfort did not settle or the lump altered further in any way.

Mr L returned to the practice five months later, reporting that over the preceding seven or eight weeks the lump had increased in size and “felt different”. On examining the lump, Dr C found it to have significantly increased in size to approximately 8cm x 5cm and to have changed in nature, now feeling more cystic on palpation. Dr C referred Mr L for an urgent general surgical opinion but did not utilise the two-week wait process¹. This was because the local hospitals at the time were struggling with the volume of two-week wait referrals and Dr C’s experience was that patients were being seen quicker if he wrote directly to the relevant department.

Mr L was reviewed by a general surgeon three weeks later and underwent a series of further reviews and investigations, ultimately resulting in a diagnosis of chondrosarcoma. Despite extensive surgical resection, disease free margins were not obtained and Mr L suffered recurrence of the tumour and sadly died.

Mr L’s partner subsequently brought a claim for clinical negligence against Dr C, alleging that at the second and third consultations, Mr L should have been urgently referred using the two-week wait process and that the NICE guideline CG27: *Referral guidelines for suspected cancer* should have been

A troublesome lump



DR HEIDI MOUNSEY, MEDICOLEGAL CONSULTANT, MEDICAL PROTECTION



Dr C referred Mr L for an urgent general surgical opinion but did not utilise the two-week wait process. This was because the local hospitals at the time were struggling with the volume of two-week wait referrals

followed, specifically the section on soft tissue sarcomas that states:

1.13.7 In patients presenting with a palpable lump, an urgent referral for suspicion of soft tissue sarcoma should be made if the lump is:

- *greater than about 5cm in diameter*
- *deep to fascia, deep or immobile*
- *painful*
- *increasing in size*
- *a recurrence after previous excision.*

If there is any doubt about the need for referral, discussion with a local specialist should be undertaken.

It was alleged that had a two-week wait referral taken place at the time of either the second or third consultation, the required surgery would have been less extensive; the tumour would have been excised with wide tumour free margins; and Mr L would not have died.

OUTCOME

The case was reviewed by the legal team at Medical Protection, and Dr C was considered to have acted reasonably under the circumstances. It was also unclear whether the outcome for Mr L would have been any different with earlier referral as his tumour was demonstrated to be particularly aggressive with a very poor prognosis.

A number of experts were instructed, including a GP and cardiothoracic surgeon.

With respect to breach of duty, the GP expert considered that it was reasonable to consider the lump to be a lipoma at the time of the first presentation and to advise Mr L to return. The expert deemed that Dr C was an experienced GP and would have been able

to clinically diagnose a lipoma, based on his familiarity with the appearance and feel of such masses.

It was also acceptable to continue a “watch and wait” approach at the time of the second consultation and reiterate to Mr L that he should return should the lump change in any way. It was noted that Mr L attributed the discomfort from the mass as relating to his new exercise regime and that it was not uncomfortable at rest. The expert therefore considered that the guidelines for referral in relation to a suspected soft tissue sarcoma were not met.

At the third consultation regarding the lump, following the significant change in size and nature, the expert considered that urgent referral was warranted. The expert further considered that Dr C’s approach in referring urgently to the general surgical department rather than via the two-week wait process was reasonable, given the hospitals in the local area at the time were struggling to process two-week wait referrals and many were being delayed or rejected.

The cardiothoracic expert considered that, with a two-week wait referral at the third consultation (rather than the urgent referral made to the general surgeons), the nature, extent, and outcome of surgery would not have been different, and Mr L would still have died when he did. Had a two-week wait referral taken place at the time of the second consultation, when the mass was significantly smaller, then the extent of surgery is likely to have been less but, given the aggressiveness of the tumour, it may well have been the case that the resected margins would not have been free of disease. However, there would have been a greater likelihood of obtaining tumour free margins (and therefore increasing the chance of survival) had surgery taken place at this time.

A letter of response was sent to the solicitors acting on behalf of Mr L’s partner denying breach of duty and causation. The solicitors subsequently indicated they intended to continue pursuing the claim and therefore a trial date was set.

Medical Protection met with the experts and Dr C in conference and concluded that the claim remained defensible, and the next step would be to prepare for trial.

At trial, the judge considered that the second consultation conducted by Dr C was in accordance with a responsible body of GPs and there was no breach of duty.

However, the judge found there to be a breach of duty with respect to the third consultation and the decision to make

REFERENCE

1. This case took place in England. The two-week wait is an NHS England rule that the maximum waiting time for suspected cancer should be two weeks from the day an appointment is booked through the NHS e-Referral Service, or when the hospital or service receives the referral letter.



With respect to breach of duty, the GP expert considered that it was reasonable to consider the lump to be a lipoma at the time of the first presentation and to advise Mr L to return

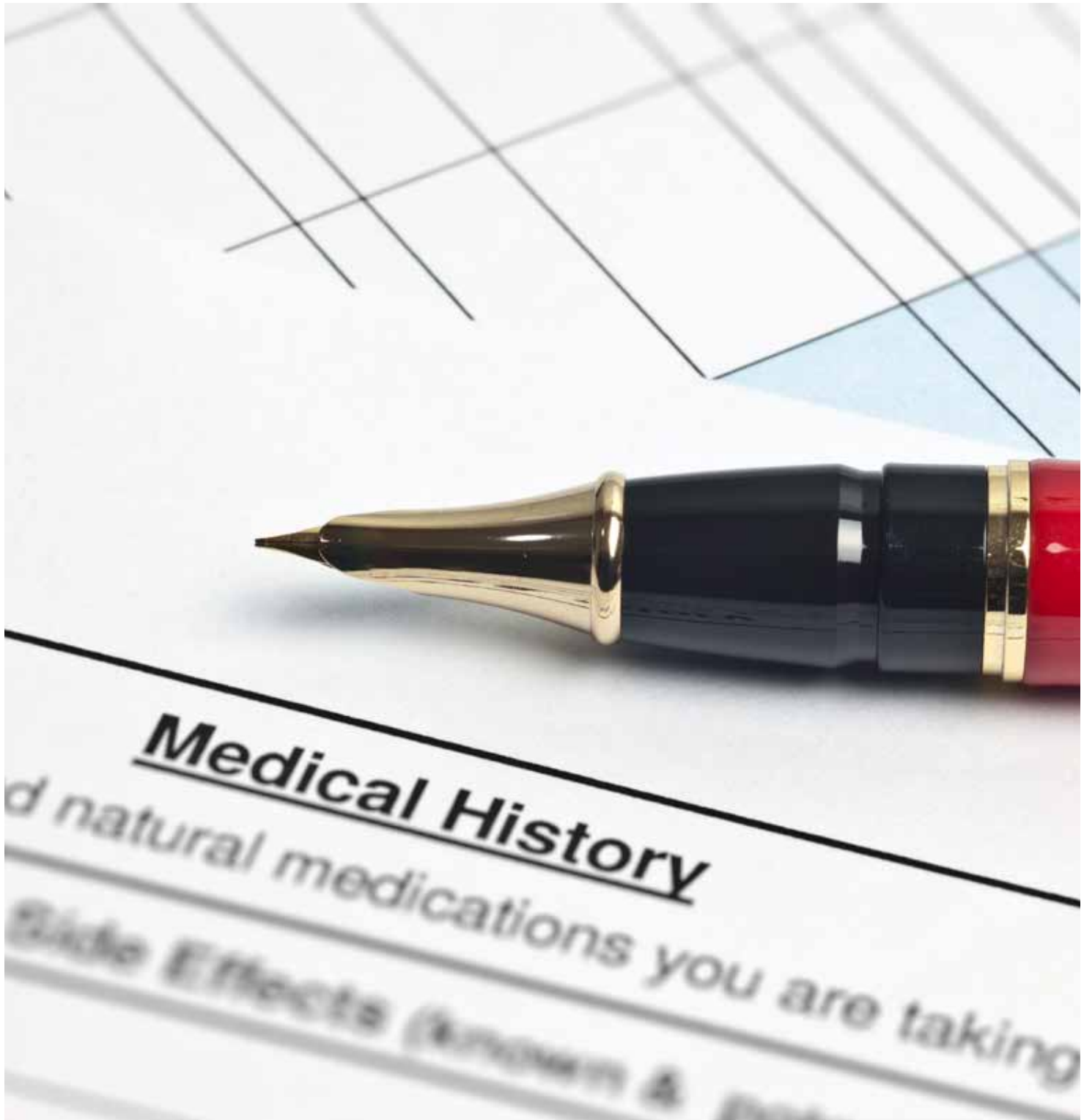
the referral to general surgery urgently by letter rather than under the two-week wait process, despite the issues described by Dr C with respect to two-week wait referrals at the relevant time. The judge, after hearing the evidence presented by the GP expert acting for Mr L’s partner, considered that additional steps, such as a phone call, could have been taken to ensure the referral was not rejected or delayed.

Conversely, the judge, after hearing evidence from the two cardiothoracic surgeons instructed in the case, preferred the view of the expert instructed by Medical Protection and determined that even had referral under the two-week process been made at the time of the third consultation, the nature of the surgery undertaken and the outcome for Mr L would still have been the same.

The judge concluded there was no causation in relation to the breach of duty and that no damages were awardable to Mr L’s partner.

LEARNING POINTS

- **This case highlights the importance of being cautious if you choose not to follow standard procedures. Be aware of local policies and processes and follow them where appropriate, but if in your clinical judgment it is necessary to deviate from these then document your reasons for this carefully and be prepared to justify your decision.**
- **Give clear advice to patients about when to return if symptoms worsen or do not settle, and ensure this advice is documented. In this case, Dr C clearly documented the advice provided and Medical Protection was able to use the records to demonstrate that Mr L had been advised to return if there were any changes to the lump.**



A rare diagnosis that seemed common



DR HEIDI MOUNSEY, MEDICOLEGAL CONSULTANT, MEDICAL PROTECTION



rs K, a 42-year-old insurance clerk, had a history of dysmenorrhea for which she took the combined oral contraceptive pill (OCP).

She contacted her GP practice and spoke to Dr F to say that she had experienced heavy bleeding with clots that morning, despite the OCP, and had suffered with gripping abdominal pain the evening before, which had now settled. Dr F suggested a trial of tranexamic acid to take as needed when Mrs K's periods were heavy, and advised her to book an appointment for a pelvic examination.

Mrs K attended the surgery for a face to face appointment some four weeks later, complaining of ongoing heavy periods and abdominal pain, and was reviewed by Dr A. Pelvic examination was found to be difficult due to Mrs K's obesity and heavy bleeding and Dr A referred her for a pelvic ultrasound scan as well as requesting a range of blood tests, including a full blood count and CA125. The blood tests revealed Mrs K to be slightly anaemic, which was attributed to the heavy menstrual bleeding.

The ultrasound scan took place two weeks later and revealed two large fibroids. A referral to gynaecology was recommended. Dr F discussed the results with Mrs K over the telephone and established that Mrs K was experiencing bloating after eating, with intermittent abdominal pain, and that she wished to be referred to gynaecology for consideration of surgery. A referral to gynaecology was duly made.

A further two weeks passed and Mrs K contacted the surgery again, undertaking a telephone consultation with Dr F where she described an episode of severe abdominal pain throughout the night that had now settled. This was considered to be due to the fibroids and mefenamic acid was prescribed.

One week after this Mrs K underwent a further telephone consultation with Dr F, complaining of ongoing abdominal bloating, and three episodes of vomiting the previous day. It was noted that Mrs K tended to vomit when her period was due and she was prescribed co-codamol as she was finding mefenamic acid to be ineffective. Her gynaecology appointment was noted to be due in two weeks' time.

The gynaecology team repeated the pelvic ultrasound and, due to poor views, requested an MRI scan for better imaging of the fibroids. This revealed a very large fibroid and Mrs K was counselled for laparoscopic hysterectomy, although she was advised she needed to lose weight before this could take place.



Mrs K was ultimately admitted to hospital with severe abdominal pain and a raised temperature, suspected to be caused by ascending cholangitis

Over the next few months, Mrs K continued to present to the GP practice complaining of spasmodic upper abdominal pain, vomiting and bloating. A diagnosis of biliary colic was considered and she was referred firstly for an ultrasound scan to assess for the presence of gallstones, and then to the gastroenterology team. Although the ultrasound scan did not demonstrate gallstones, both the gastroenterology team and GPs continued to consider biliary colic was the most likely cause for her ongoing but intermittent symptoms.

Mrs K was ultimately admitted to hospital with severe abdominal pain and a raised temperature, suspected to be caused by ascending cholangitis. However, investigations revealed a small bowel stricture and she underwent an emergency laparotomy and small bowel resection. Histology demonstrated a small bowel adenocarcinoma. She was advised to undergo adjuvant chemotherapy.

Mrs K subsequently brought a claim against Dr F, alleging that she was experiencing severe pain at the time of the initial telephone consultation and should have been advised to attend the practice the same day for a face to face appointment. It was also alleged that subsequent to reporting an episode of severe abdominal pain that had lasted throughout the night, Dr F should have arranged a face to face same day appointment for examination and review, and again at the time Mrs K reported vomiting.

Had she been reviewed in person on these occasions, it was alleged that she would have been referred to secondary care earlier and the tumour would have been identified at an earlier time point, therefore preventing several months of unpleasant symptoms and allowing surgery to be performed in an elective manner.

Further allegations were made against other clinicians who had reviewed Mrs K during this time.

OUTCOME

The case was considered by Medical Protection's medical and legal team, and Dr F was considered to have acted appropriately. The team also felt that it was unlikely that, even had Mrs K been seen face to face on any of these occasions, or referred sooner to secondary care, the tumour would have been identified significantly earlier than it was.

A GP expert was instructed. The expert was clear that, on the basis of the medical records and Dr F's comments, it was not mandatory to offer a face to face appointment the same day as any of her telephone consultations.

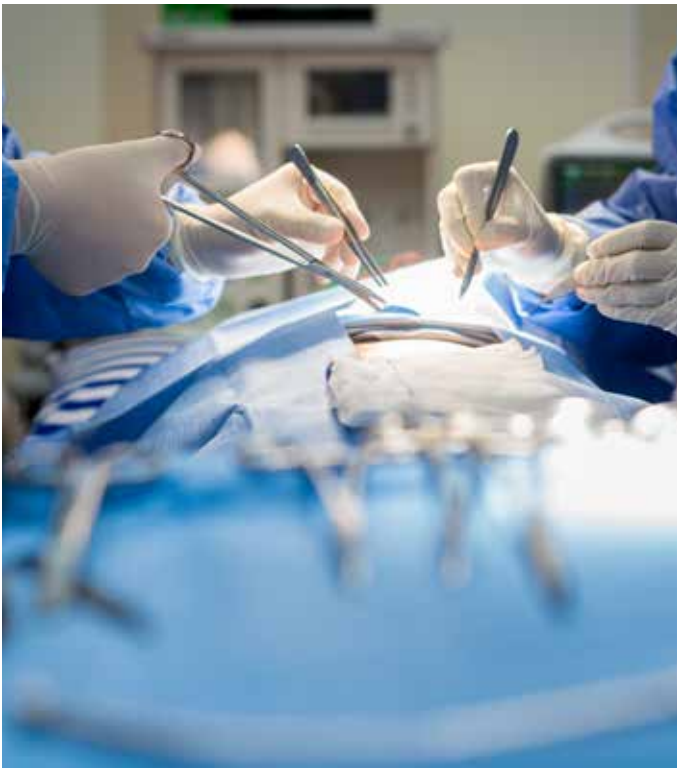
The expert did, however, comment that had symptoms been ongoing at the time of the consultations, then Dr F should have established the severity of the pain or vomiting and likely offered a same day appointment for review and examination.

On receipt of the expert report, the case was again fully reviewed by Medical Protection's medical and legal team and it was agreed that a letter of response, defending the actions of Dr F, should be drafted, and that the offer of early settlement by Mrs K's solicitors should be rejected.

Following receipt of the letter of response, Mrs K's solicitors discontinued the claim against Dr F.

LEARNING POINTS

- **Comprehensive and unambiguous documentation of the patient's symptoms at the time of a telephone consultation is vital should the history obtained ever be challenged at a later date.**
- **The need for a face to face appointment should always be considered, especially if the patient is a poor historian or there is doubt about the nature or severity of the symptoms.**
- **If a patient is repeatedly contacting the surgery for telephone consultations about the same symptoms, it may be prudent to offer a face to face appointment to discuss the symptoms further and perform any appropriate examination or investigations.**
- **In the event a patient's symptoms do not settle, it may be advisable to reconsider the working diagnosis in light of the information available and weigh up whether an alternative, perhaps rarer, diagnosis may be the cause.**
- **Clinicians should be mindful that a patient may have more than one pathology contributing to their symptoms.**



Could it be cauda equina?



DR MARIKA DAVIES, MEDICOLEGAL CONSULTANT,
MEDICAL PROTECTION

A 49-year-old self-employed business owner with a long history of back pain was referred to Dr A, a spinal surgeon. The patient had undergone three discectomy procedures over the course of the previous two years, which had not resolved his pain.

Dr A carried out a revision decompression at the L5/S1 level, posterior lumbar interbody fusion at L5/S1 and an instrumented fusion from L4 to S1. Following the surgery the patient continued to suffer with pain. Dr A diagnosed pseudoarthrosis at the level of L4/5 and carried out further surgery with revision of the fusion and insertion of a cage at the L4/5 level. Unfortunately, the patient developed a leak of spinal fluid, which led to a further two revision procedures by Dr A.

The patient brought a claim against Dr A and the hospital. He alleged that the first revision procedure was substandard and caused the spinal fluid leak, which was not properly repaired. He also alleged that he was discharged from hospital too soon after the second revision procedure, and that he was left with urinary catheter material in his bladder which required surgical removal a year later. The patient alleged that the third revision surgery was negligent and failed to resolve his ongoing symptoms. He said he had an ongoing lack of feeling in his right leg with paralysis from the knee down and was suffering from ongoing pain, a neuropathic bladder, and sexual dysfunction. The patient later claimed his symptoms were the result of a cauda equina syndrome (CES) at the time of the second revision surgery, which he alleged Dr A had failed to identify and treat.

Medical Protection obtained expert evidence from a neuroradiologist and a neurosurgeon who were both supportive of Dr A's management.

The case went to trial. On the first day of the trial, the claimant settled their case involving the retained piece of catheter with the hospital.

Dr A's defence team argued that the claimant did not have CES and that his ongoing urinary symptoms were a result of the retained piece of catheter and not as a result of nerve compression, given the results of urodynamic studies. MRI scans taken at the time did not show any haematoma which might put pressure upon the cauda equina nerves and surgical intervention was not required.

The judge made a finding in fact that the claimant had developed CES leading to pressure on the nerves and the subsequent sequelae. He accepted the claimant's expert opinion that the MRI showed developing CES and that it was there before the second revision procedure. He also found that had intervention occurred earlier he would not have developed CES.

However, the judge did not find Dr A negligent for his interpretation of the scan. He accepted the defence submissions that Dr A had adopted a "gold standard approach" to his care of the claimant and that his actions could not be faulted or described as negligent despite the findings of fact.

The claim was successfully defended and judgment was made in favour of Dr A.

LEARNING POINTS

- An adverse outcome for the patient does not necessarily mean there was negligence on the part of the doctor.
- In defending a claim of clinical negligence you must be prepared to explain and justify your management decisions.
- The role of the expert is to provide the court with an independent opinion on the clinical issues in the claim. Expert evidence on the standard of care provided can be pivotal to the outcome of a case.
- It is rare for claims for negligence against doctors to progress as far as a trial – the vast majority are settled, successfully defended, or discontinued before the case reaches a courtroom.



Missed case of ovarian cancer goes to trial



DR MARIKA DAVIES, MEDICOLEGAL CONSULTANT,
MEDICAL PROTECTION

A 36-year-old woman presented to her GP complaining of a six month history of abdominal bloating and urinary frequency. The GP referred her to a gynaecologist, who assessed the patient and requested a pelvic MRI scan. The scan was reviewed by Dr D, a radiologist, who reported that it was within normal limits with no pathology and that both ovaries were normal.

Over the next few months, the patient continued to experience abdominal pain and bloating.

A few months later, she was referred by her GP to hospital with shortness of breath and right pleuritic chest pain. An x-ray showed bilateral pleural effusions and a right pleural drain was inserted. A few days later, the patient discharged herself against medical advice, but was seen in the clinic a few days later, where a left pleural drain was inserted.

A CT of the thorax, abdomen and pelvis showed a bilateral pleural effusion and bilateral enlarged ovaries. The right ovary was reported as 5cm in size, with a complex appearance, and it was noted that there were multiple enhancing mesenteric/peritoneal nodular deposits. The conclusion was of a suspicious ovarian mass with evidence of peritoneal and omental infiltration.

The cytology from the pleural effusion confirmed the presence of adenocarcinoma cells of gynaecological origin. The patient was diagnosed with stage IV ovarian cancer and given a terminal prognosis.

She brought a claim against the radiologist Dr D, who was a Medical Protection member, alleging that he had failed to detect features

of bilateral ovarian cystadenocarcinoma, which had led to a seven-month delay in diagnosis of her condition. An expert radiologist instructed by the claimant reviewed the MRI scans that had been reported by Dr D and considered there was a lobulated septated cystic mass on the right ovary.

Medical Protection obtained expert evidence from a specialist in gynaecological imaging, who was supportive of Dr D's interpretation of the MRI scan.

The case progressed to a trial.

When giving evidence, the expert radiologist instructed by Medical Protection showed the court a number of slides to assist in its understanding of the clinical situation. The slides showed normal ovaries, abnormal ovaries and finally images of the patient's ovaries. The expert explained what a radiologist would be looking out for and demonstrated that none of those concerning features were present in the images of the patient's ovaries.


In addition, the member brought his laptop and connected it to a large screen so he could show the court in real time what his routine practice was when reviewing ovaries, which particular features he would be specifically looking out for, and why he was satisfied there was nothing abnormal in this case.

The trial judge ultimately considered the evidence of the Medical Protection expert to be more convincing.

The judge was very sympathetic to the patient and her family; however, he found in favour of the member and dismissed the patient's case.

LEARNING POINTS

- The case turned on the reporting of the MRI scan – if the court had accepted there were features of ovarian cystadenocarcinoma present on the initial scan then it might have been difficult to defend the case on causation.
- The primary function of professional medical experts is to provide the court with an independent opinion on the clinical issues involved in a case to help the court make a decision on questions falling within that expert's specialist field. An expert must assimilate the facts of the case, consider the questions asked of them, and formulate an opinion on the clinical issues based on their experience and qualifications.
- Where the court is presented with differing expert opinion, it is up to the judge to decide which expert evidence they most agree with, and this may be influenced by a number of factors.
- In this case, the Medical Protection expert was instructed 'blind' without the benefit of the final diagnosis, in contrast to the patient's expert who was advised of the diagnosis at the time of his instruction.
- In addition, the Medical Protection expert was still in clinical practice and had a great deal of practical experience reporting on MRI scans in a clinical setting. The patient's expert was retired and had reported on MRIs for research purposes in the last ten years of his practice.



The GP harassed by a patient



DR JAYNE **MOLODYN**SKI, MEDICOLEGAL CONSULTANT, MEDICAL PROTECTION



P Dr S contacted Medical Protection about a complaint from a patient who was frustrated with the practice's new appointment system. The patient said she was struggling to make an appointment with her preferred GP who was often booked up for a couple of weeks ahead.

Dr S spoke with an adviser from the Medical Protection advisory team, who talked him through the process of handling complaints in the practice. She advised Dr S to acknowledge the complaint and explained the complaints procedure, sending him the Medical Protection guide to managing complaints and guidance on writing the response. The adviser also reviewed the proposed response before it was sent to the patient.

Dr S contacted Medical Protection again several weeks later in relation to a letter he had received from the same patient. She had written to the practice asking for Dr S to be her named GP. The practice manager had shared the letter with the partners as it contained a number of compliments about Dr S. They had discussed the issue at a meeting and were unsure how best to manage the situation.

After a discussion with Medical Protection's advisory team, Dr S decided to agree to be the patient's named GP as he felt that they had established a good doctor-patient relationship whilst he was managing her complaint and he didn't feel any of the comments in her letter were of a personal nature.



The police advised Dr S that if the behaviour continued they may consider a caution or further action under harassment laws

Several years later, Dr S contacted Medical Protection to request further advice regarding this patient. Dr S explained that he was moving practices due to family reasons and that when the patient had been advised of this, she had emailed him directly to ask where he was going so that she could register there. Dr S explained that he was moving out of the area; however, the patient was persistent in trying to find out where he was going, to the extent that she tried to obtain this information from other members of staff at the practice.

Understandably Dr S and the practice were finding this situation challenging, particularly as the patient was now refusing to see any other GPs at the practice. After discussing events with Medical Protection, the partners decided to write to the patient explaining that as Dr S was leaving the practice, she would be assigned an alternative named GP. The patient was offered a meeting to discuss matters further should she want to do so.

It appeared that the matter had been resolved, as the patient accepted the change in GP and Dr S moved shortly after. However, a few weeks later Dr S saw the patient leaving his new practice and, after making enquiries, he was advised by the practice manager that she had applied to register with them. Her application was declined as she did not live within the practice boundary and was unable to provide any reason why she needed to be registered with the practice. Dr S was hopeful that would be the end of the matter. Unfortunately, he began to receive cards at the practice in which the patient expressed her wish to meet with him. Dr S contacted Medical Protection again at this stage.



Dr S explained that he was moving out of the area; however, the patient was persistent in trying to find out where he was going

The Medical Protection advisory team advised the GP to ask the original practice to write to the patient and to invite her to meet with a GP there. Regrettably matters escalated and the patient began sending more letters to Dr S, calling the practice continuously to try to speak to him; she was also seen in the car park on a couple of occasions. The patient subsequently visited Dr S at home, twice shouting outside his door at him and his family.

At this stage Medical Protection instructed solicitors to review the case, and they wrote to the patient advising her that should she continue to harass Dr S in any way, they would issue civil proceedings for harassment against her.

Dr S also contacted the police, who attended to take a statement in case the letter was not effective and the patient continued to harass him. The police advised Dr S that if the behaviour continued they may consider a caution or further action under harassment laws.

OUTCOME

Fortunately, after receiving the correspondence from the solicitors the patient made no further attempts to contact Dr S.

LEARNING POINTS

- Medical Protection is frequently contacted by members seeking advice and support about challenging doctor-patient relationships. This may relate to a breakdown in a relationship with a patient due to their behaviour, where a practice is seeking guidance about whether it would be appropriate to remove a patient from the list or, as in this case, seeking advice about a patient who may be forming an inappropriate attachment to their GP. Fortunately, not many cases escalate to the extent of the one described above.
- If a patient pursues a sexual or improper emotional relationship with you, you should treat them politely and considerately and try to re-establish a professional boundary. If trust has broken down you may find it necessary to end the professional relationship.
- These can be emotive situations and can put a doctor under a significant degree of stress. It is not always apparent what a patient's intentions or motivations are, particularly in the earlier stages.
- As highlighted in this case, Medical Protection can also instruct solicitors to write to patients who are harassing a doctor to set out the possible consequences of their actions.

Over to you

Forgotten blood test results: forgotten patient

This case in May's edition of *Casebook* contained some important considerations for all doctors involved in paediatric practice. It is extremely common to handover the task of chasing 'routine' blood results performed by the day team to the on-call team. The prime example of this is the newborn jaundice clinic. It is understandable that these tasks can be overlooked by the clinicians managing a ward full of patients as well as unwell children presenting to A&E out of hours.

In order to prevent these results being forgotten as occurred in this case review, it is vital that paediatric units have systems in place to enable efficient follow-up of results. The utilisation of a simple 'results to be chased' folder has proven effective in the unit where I have worked (although we remain reliant on pieces of paper, so this is far from foolproof), avoiding the repeated handover of information and keeping the chasing of routine results as the responsibility of the day team.

I have expressed my concerns about how the results are communicated to parents and GPs. In some units all parents are told to expect a phone call with the results. This puts the onus on the parents to chase if they have not been contacted, which I feel leaves clinicians vulnerable to similar litigation as in the discussed case.

In other units a simple clinic letter with the blood results is forwarded to the GP. I feel that this is a more effective method of communication, ensuring the GP is aware that the child has been assessed by the paediatric team, blood tests performed and these results reviewed.

Dr Nicole McGrath, Paediatric registrar, UK

Delayed diagnosis of lung cancer

I am a thoracic surgeon with a lung cancer interest.

I read your report on the case ("Delayed diagnosis of lung cancer", *Casebook* 27(1)) in the May 2019 issue of a small cell lung cancer diagnosis and a patient claim that a chest x-ray from seven years earlier represented a missed diagnosis opportunity.

This is not biologically correct in regard to small cell lung cancer. It is inconceivable that small cell lung cancer would have such a long lead time.

Obviously a short summary piece like this can't hold all the details of the case and maybe there is more to it, but this would appear to be a case where oncology science and biology have not been considered. On the short details presented, there would not appear to be a case.

I note, however, that the point of your message related more to the communication/multiple doctors involved. Was this a real case at all or just to illustrate the system failure points?

David G Healy, Associate Clinical Professor, Ireland



While there were some aspects changed for anonymity, this is a real case and the timescales are comparable to those that actually occurred. There were a number of issues that led to the outcome of settlement in this case – it was a very different jurisdiction (outside Ireland and the UK), and the bulk of the claim was settled by the hospital with a contribution from Medical Protection.

Initial management of itchy skin rash

In reference to "Initial management of itchy skin rash" (*Casebook* 26(2)), November 2018, and the differential diagnosis of a blistering rash: bullous pemphigoid can present as an urticated itchy rash for months before blisters come up; even a biopsy does not help in diagnosis, indirect immunofluorescence. Bed bugs are also notorious (and you did mention insect bites).

Scabies is terribly itchy and most patients call any rash 'blisters'; sometimes the index or causative patient may have Norwegian scabies

and is asymptomatic because of stroke/dementia. Gloves should always be worn when examining patients with a widespread rash.

Sunburn, chemical irritants and folliculitis seldom cause blistering rashes.

Dr S Tharakaram, Dermatologist, UK

CORRECTION In the previous edition of *Casebook* (Vol 27 Issue 1, May 2019), we erroneously attributed the letter titled "A sight for sore eyes" to Dr John McGough. The correspondent was in fact Dr David Levy. We apologise for the error.

Medical
Protection



HERE TO PROTECT YOU AND YOUR PROFESSIONAL REPUTATION

Learn how to manage your risk
and improve patient safety

Our **FREE** risk prevention tools and
techniques include:

- Online learning
- Lectures and seminars
- Workshops

REGISTER TODAY AT
MEDICALPROTECTION.ORG/PRISM

Find us on   @MPS_Medical

CONTACT US

MEDICAL PROTECTION

Victoria House
2 Victoria Place
Leeds LS11 5AE
United Kingdom

info@medicalprotection.org

In the interests of confidentiality please do not include information in any email that would allow a patient to be identified.

MEDICOLEGAL ADVICE

For medicolegal advice please call **+44 113 243 6436** or complete the contact form on our website, medicalprotection.org.

Calls to Membership Services may be recorded for monitoring and training purposes

MEMBERSHIP ENQUIRIES

Barbados

Barbados Association of Medical Practitioners
Tel **(246) 429 7569**
info@bamp.org.bb

Jamaica

Andrew Bromfield
Tel **(876) 999 0575**
alexbrumfield.ab@gmail.com

Trinidad and Tobago

Trinidad and Tobago Medical Association
Tel **(868) 671 7378**
medassoc@tntmedical.com

Anguilla, Antigua and Barbuda, The Bahamas, Belize, Bermuda, British Virgin Islands, Cayman Islands, Dominica, Grenada, Guyana, Montserrat, St Kitts and Nevis, St Lucia, St Vincent and the Grenadines, Turks and Caicos

Tel **+44 113 243 6436 (UK)**
Fax **+44 113 241 0500 (UK)**
caribbeanandbermuda@medicalprotection.org

The Medical Protection Society Limited ("MPS") is a company limited by guarantee registered in England with company number 00036142 at Level 19, The Shard, 32 London Bridge Street, London, SE1 9SG.

MPS is not an insurance company. All the benefits of membership of MPS are discretionary as set out in the Memorandum and Articles of Association. MPS® and Medical Protection® are registered trademarks.