

Professional support and expert advice  
from your leading medicolegal journal

# CASEBOOK

VOLUME 26 | ISSUE 2 | NOVEMBER 2018

ASIA



## A cyst in time

A LESION IS REMOVED BUT WHAT ELSE HAS BEEN MISSED?

### From the case files

#### **NAUSEA AND WEIGHT LOSS – WHAT'S THE CAUSE?**

Dr W faces a regulatory hearing after a delayed diagnosis.

#### **A WRONG DIAGNOSIS BUT NO CRITICISM**

After a serious car crash, Dr C is called before an inquest.

#### **INITIAL MANAGEMENT OF AN ITCHY SKIN RASH**

Treatment of an itchy rash leads to a claim against GP Dr U.



# LIKE YOU, WE BELIEVE **PREVENTION** IS BETTER THAN CURE

We are here to help stop problems from happening in the first place.

Get advice and support on issues like consent and protecting confidentiality

- ✓ Talk to our expert doctors with legal qualifications
- ✓ Local and free risk management workshops
- ✓ Factsheets and case reports



Find out more at [medicalprotection.org](https://www.medicalprotection.org)

# What's inside...

## Every issue



### Welcome

Dr Marika Davies, Editor-in-Chief of Casebook, welcomes you to this edition and comments on some topical issues.

### Over to you

What did you think about the last issue of Casebook? All comments and suggestions welcome.

## Case reports



06

### A wrong diagnosis but no criticism

After a serious car crash, Dr C is called before an inquest – Medical Protection is called in to support.



07

### Initial management of an itchy skin rash

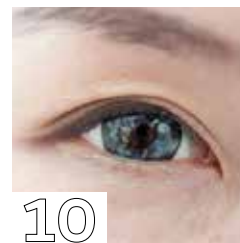
Treatment of an itchy rash leads to a claim against GP Dr U, but was he negligent?



08

### Negligent assessment and systemic failures

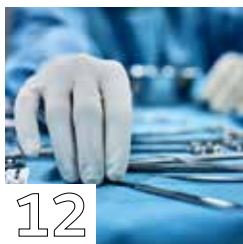Two hospital doctors receive claims after a delayed cancer diagnosis, which Medical Protection eventually takes to trial.



10

### A sight for sore eyes

Ophthalmologist Dr P receives a claim alleging poor consent and technique – but is that the real cause?



12

### A cyst in time

Mrs D presents to her GP Dr N with a long-standing lesion on her scalp. Dr N removes it but what has he missed?



13

### Who else is in the room?

A patient undergoing a colonoscopy claims her modesty is disregarded during the procedure. What did Medical Protection do to tackle this allegation?



14

### Questioning your consultant

A disagreement between a specialty trainee and her consultant lies at the heart of a regulatory hearing following a patient's death.



16

### Nausea and weight loss – what's the cause?

Dr W faces a regulatory hearing after a delayed diagnosis – find out how record-keeping helped the defence.

Opinions expressed herein are those of the authors. Pictures should not be relied upon as accurate representations of clinical situations. © The Medical Protection Society Limited 2018. All rights are reserved.

ISSN 1366 4409

Casebook is designed and produced twice a year by the Communications Department of the Medical Protection Society (MPS). Regional editions of each issue are mailed to all MPS members worldwide.

GLOBE (logo) (series of 6)® is a registered UK trade mark in the name of The Medical Protection Society Limited.

The Medical Protection Society Limited ("MPS") is a company limited by guarantee registered in England with company number 36142 at Level 19, The Shard, 32 London Bridge Street, London, SE1 9SG.

MPS is not an insurance company. All the benefits of membership of MPS are discretionary as set out in the Memorandum and Articles of Association. MPS® and Medical Protection® are registered trademarks.

Cover: @XiXinXing/GettyImages.co.uk

Casebook publishes medicolegal reports as an educational aid to Medical Protection members and to act as a risk management tool. The reports are based on issues arising in Medical Protection cases from around the world. Facts have been altered to preserve confidentiality.

Get the most from your membership...



Visit our website for publications, news, events and other information: [medicalprotection.org](http://medicalprotection.org)



Follow our tweets at: @MPS\_medical



Top tips in the palm of your hand – download the free MPS Advice app on the App Store or Google Play

## Editorial team



DR MARIKA  
**DAVIES**  
EDITOR-IN-CHIEF



GARETH  
**GILLESPIE**  
EDITOR



DR JANET  
**PAGE**  
EDITORIAL CONSULTANT



ANTOINETTE  
**COLTSMANN**  
EDITORIAL CONSULTANT

## Case report writers



DR CLARE  
**DEVLIN**



DR GERARD  
**MCKEAGUE**



DR ANUSHA  
**KAILASANATHAN**



DR ELLEN  
**WELCH**

### PRODUCTION

**Emma Senior** Corporate Design Manager  
**Conor Walsh** Senior Designer  
**Print** Spellman Walker

### Please address all correspondence to:

Casebook Editor, Medical Protection, Victoria House, 2 Victoria Place, Leeds LS11 5AE,  
United Kingdom  
[casebook@medicalprotection.org](mailto:casebook@medicalprotection.org)

## Welcome

DR MARIKA  
**DAVIES**  
EDITOR-IN-CHIEF



**I**n the last edition of *Casebook* I wrote about the UK case of Dr Hadiza Bawa-Garba, who was erased from the medical register by the General Medical Council. The case had disturbing implications for openness in healthcare, with doctors understandably concerned about how Dr Bawa-Garba's written reflections and e-portfolio were used in the case. So we greatly welcomed the decision in August to overturn this ruling and reinstate Dr Bawa-Garba.

While not forgetting that there was a terrible tragedy in this case – and a grieving family who lost their young child – the impact of Dr Bawa-Garba's reinstatement is significant for all doctors. When errors occur in medicine, their causes are often complex and the result of a variety of issues, such as human factors and systemic failings; not necessarily the fault of one individual.

Systemic failings are often at the heart of the case reports in *Casebook*, and this edition is no different. In the case "Negligent assessment and systemic failures?", we fought a clinical negligence claim on behalf of two hospital doctors who were at the mercy of an inadequate hospital notification system for following up abnormal x-rays. While neither doctor was completely absolved of error, they ultimately did not contribute directly to the patient's death – and we were committed to fighting the claim all the way to trial, where we were eventually successful in defending both members.

I am also pleased to be able to showcase many other areas of support that Medical Protection offers, with case reports drawn from medicolegal scenarios as diverse as inquests and regulatory hearings. There are even some particularly complex cases that cross a number of different areas of jeopardy – a complaint can become a claim, then a regulatory hearing, and may also involve an inquest – yet they emanate from one single incident.

But rather than completely dispirit you, it is my hope that this diverse collection of cases provides you with reassurance that Medical Protection is equipped to assist you with many different types of case. Whether it be expert representation in a claim or regulatory hearing, or support, guidance and advice through an inquest or employer disciplinary, the expertise of Medical Protection is truly wide-ranging.

As ever, if you wish to share your views on *Casebook* or any other issue, I would be happy to hear from you.

**Dr Marika Davies**  
**Editor-in-Chief**

[marika.davies@medicalprotection.org](mailto:marika.davies@medicalprotection.org)



# Senior healthcare leaders appointed to MPS Council

**T**wo senior doctors will take up leadership roles at MPS, following the confirmation of Professor Dame Jane Dacre as President and Mr Ian Eardley as the new Chair of MPS Council.

**Professor Dacre** has served as President of the Royal College of Physicians in the UK since 2014. She is a consultant physician and rheumatologist at the Whittington Hospital in north London, and was formerly director of University College London Medical School. Professor Dacre is also leading an evaluation of the effects of gender and ethnicity on the career trajectories and performance of women doctors, and was awarded Woman of Achievement in medicine and healthcare in 2012 by Women in the City. She was in the inaugural *Health Service Journal* list of inspirational women in healthcare in 2013.

Commenting on her appointment as President, Professor Dacre said: "I am delighted to be joining MPS as their new President. Healthcare professionals around the world face very real challenges and increasing pressure in their daily working lives.

"They are expected to meet rising patient expectations, often in challenging working conditions and with the prospect of personal accountability when things go wrong. I look forward to bringing my experience to MPS to ensure we can provide the best protection to members."



**Mr Eardley** sits on the Council of the Royal College of Surgeons of England; until July 2018 he was the vice president, a role he took on in 2015 after previously being elected to the Council in 2010. He is a consultant urologist at Leeds Teaching Hospital Trust and works at St James University Hospital, both in the UK. In 2014 he was awarded the St Peter's medal by the British Association of Urological surgeons for his contribution to the advancement of urology. Mr Eardley has extensive experience in surgical education and training, and has been Chairman of the Joint Committee for Surgical Training. He has been a member of MPS Council since November 2015.

Commenting on his appointment as Chair of MPS Council, Mr Eardley said: "As Chair of Council I will ensure that MPS continues to evolve so it can continue to meet members' changing needs while ensuring that the service we offer to members remains as strong, robust and relevant in the future as it has always been."

Since 2012, MPS Council has benefited from the chairmanship of Prof Kay-Tee Khaw, alongside Professor Sir Ravinder (Tiny) Maini, who since 2015 has been the President. Professor Khaw will stay on as a member of MPS Council until June 2019.

Mr Eardley took up his post as Chair of MPS Council on 19 September and Professor Dacre on 1 October, after she stood down as President of the Royal College of Physicians on 26 September.

Simon Kayll, Chief Executive of MPS, said: "Jane and Ian are both well-known to our members and MPS is fortunate to have secured two eminent and respected healthcare leaders to take up these vital roles on the Council.

"I would also like to thank the previous role holders, Kay-Tee and Ravinder, for their support and hard work. They have both brought an unparalleled level of expertise and insight to the Council during their tenure."



# A wrong diagnosis but no criticism



BY DR GERARD MCKEAGUE, GP

**M**r G, 28, was brought into hospital by ambulance following a motorway accident involving multiple casualties. He had been unable to stop in time and had driven into the back of the car in front. Although the force of the collision had been sufficient to deploy the airbag in Mr G's car, he was fully conscious on arrival at hospital and was able to give a clear account of what had happened.

Mr G was assessed by Dr C in the Emergency Department, who recorded the patient to be fully alert and oriented with GCS 15. She noted a non-tender abdomen, chest clear to auscultation, good air entry on both sides, with no obvious signs of injury. X-rays of the cervical spine were deemed unnecessary as Mr G was assessed as meeting the NEXUS criteria and therefore his cervical collar was removed.

Mr G was kept in the resuscitation area and, over the next 60 minutes, he became increasingly anxious, asking repeatedly about the other casualties and wanting to know if his partner who had been travelling with him was safe. They had been, he said, en route to a wedding and were now probably going to miss the ceremony. Mr G mentioned a past history of anxiety attacks and said he'd had counselling, which had helped, and that he was not currently on any medical treatment.

He was reassured by nursing staff, and analgesia in the form of 1g oral paracetamol was administered. Mr G spoke again about the crash and how close he had come to going through the windscreen. He told Dr C that there had been little chance to stop his car in time and that the other vehicle was upon him before he knew anything about it. Throughout the conversation he began to breathe more

“ ”

*Mr G mentioned a past history of anxiety attacks and said he'd had counselling, which had helped*

rapidly and complained of his fingers tingling. Dr C believed that Mr G was having a panic attack so she explained to the patient that he was hyperventilating and, along with the nursing staff, attempted to calm him down. Due to Mr G's agitation, Dr C asked the nurse to give him 5mg of diazepam.

Notwithstanding this, Mr G complained of feeling claustrophobic and attempted to take off his oxygen mask. At that point his pulse rate was 122/min and regular, his blood pressure was 102/58mmHg and oxygen saturation was 91%. Dr C and the nursing staff continued in their attempt to reassure and calm him, and get him to slow his breathing down. Mr G began to shout and attempted to get up from the trolley and, while they were trying to get him to lie back down, he became limp and lost consciousness. IV access was obtained and cardiac monitoring showed pulseless electrical activity. Despite extensive resuscitation attempts, Mr G died.

A postmortem examination found a splenic rupture and intra-abdominal haemorrhage.

## OUTCOME

The case went to the coroner's court for an inquest. Dr C was called to give evidence at the inquest and Medical Protection instructed a barrister to individually represent her. In order to prepare for the inquest, a conference with the barrister, the instructed solicitor and a medicolegal consultant was arranged, where Dr C's notes were reviewed in advance.

Although Dr C had wrongly attributed Mr G's symptoms to dehydration and anxiety, based on the evidence heard during the inquest from Dr C's quality note-keeping, the coroner found that this did not necessarily mean her decision-making was flawed.

The coroner recorded a verdict of accidental death, concluding that death was due to the injuries sustained from the car crash.

## LEARNING POINTS

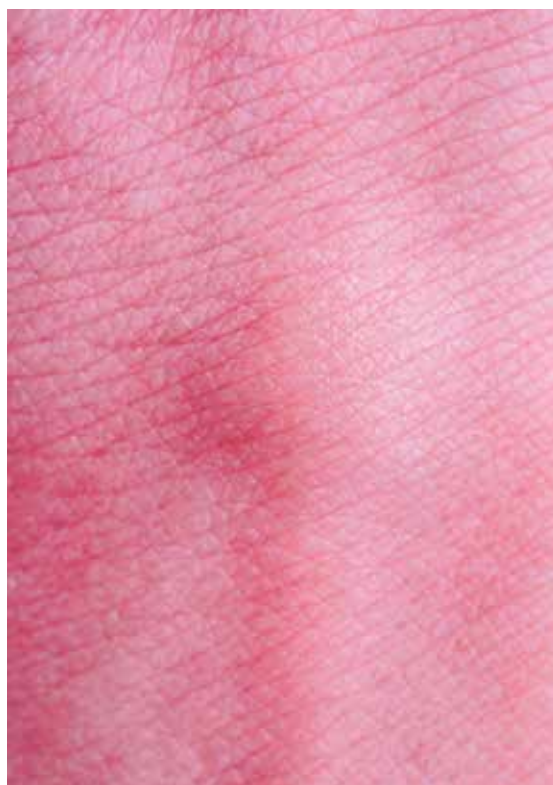- In the context of emergency presentations including trauma, be mindful that agitation may be due to an underlying physical problem (eg hypoxia, hypoglycaemia or hypovolaemia) and these should be excluded before attributing agitation to psychological causes.
- As always, good note-keeping is essential – not only for patient care, but in case of any further investigations into a doctor's actions. In this case, Dr C's clear, contemporaneous records provided essential evidence during the inquest.

## Claim

# Initial management of an itchy skin rash



BY DR CLARE **DEVLIN**, MEDICAL CLAIMS ADVISER, MEDICAL PROTECTION



**A** middle-aged woman, Mrs Y, presented to GP Dr U with a ten-day history of an itchy rash over her arms and chest, which was forming blisters. The distribution of the rash was on sun-exposed areas of skin, and the blisters were not forming scabs. Mrs Y felt the rash started after she took buscopan.

She had had chickenpox in the past. Dr U considered dermatitis herpetiformis, and arranged blood tests including full blood count, erythrocyte sedimentation rate, thyroid tests and a coeliac screen. All blood tests were normal, and the patient was given reassurance and advice.

At review with a different GP two weeks later, the rash was subsiding, but was leaving areas with a bruised appearance, which the patient was concerned about. A routine dermatology referral was planned, but unfortunately was not made for eight weeks, due to the referral task being closed in error before the referral was made.

In the dermatology clinic a few months on, the skin changes were thought to be post-inflammatory pigmentation. Mrs Y was reassured that the appearance of the patches should settle over the following months, and she was prescribed mometasone cream to assist. Unfortunately, the mometasone was not effective, and Mrs Y was referred for camouflage cosmetics to disguise them.

Mrs Y made a claim against Dr U.

### SUMMARY OF ALLEGATIONS

It was alleged by Mrs Y's solicitors that Dr U ought to have prescribed a "strong steroid cream" at the initial appointment and also made a referral to dermatology at that point.

It was alleged that had she done so, the rash would have settled sooner and the skin pigmentation requiring camouflage make up would not have occurred.

### EXPERT OPINION

Medical Protection did not obtain an opinion from a GP expert, being confident in basing our letter of response denying breach of duty on the facts of Dr U's reasonable management at the initial consultation.

The claim was not pursued against Dr U following our letter of response denying liability. A co-defendant's medical defence organisation went on to settle the claim in full on behalf of their member, who had mistakenly completed the dermatology referral task without making a dermatology referral.

### LEARNING POINTS

- In primary care, when a claim involves an administrative error, such as a delayed referral, if the individual responsible is not identifiable, then the claim falls to the responsibility of the practice partners. In this case, however, the practice was able to provide Medical Protection with an audit trail showing which staff member had marked

the dermatology referral task 'complete' in error. It was therefore possible for Medical Protection to relay this audit information to the relevant individual's legal representatives to encourage them to settle the claim without involving the practice partners.

- At Medical Protection we will ask members for their comments on the events in question when we are investigating a claim and preparing our response. In this case, we worked closely with the member to advance a robust letter of response, setting out her reasonable management at the consultation in question.
- We were able to demonstrate Dr U's reasonable management of this case through her simple reassurance and advice, followed by blood investigations, and later a dermatology referral when patient concerns persisted.
- Blistering rashes can have many causes, including sunburn, extremes of cold or heat, friction, viruses (eg chickenpox, shingles, herpes simplex), chemical irritants, dermatitis herpetiformis, pemphigus, pompholyx, insect bites, and skin infections such as folliculitis. The precise diagnosis may not be obvious, especially early in the clinical course.



Claim

# Negligent assessment and systemic failures



BY DR ELLEN WELCH, GP





## *More than three years later, Ms F presented back to the ED, this time with a low-grade fever and right-sided chest pain.*

asymptomatic, he asked her to follow up if she developed further symptoms.

More than three years later, Ms F presented back to the ED, this time with a low-grade fever and right-sided chest pain. The pain was worse on deep inspiration and she felt slightly breathless. Dr A was on duty and requested a chest x-ray, noting again the presence of a right mid-zone nodule. He compared the images to those taken three years earlier and found no change. He discussed the images with his supervising consultant, noting the previous input from a respiratory physician, and diagnosed Ms F with musculoskeletal chest pain. She was advised to return if she felt worse.

The formal report came back the following day, stating the presence of “a rounded opacity measuring 2.2cm in the right mid-zone of the lung which appears stable since the previous x-ray”. A follow-up radiograph was suggested; however, the report was not flagged as abnormal by the radiologist, so was not routed back to the ED for follow up.

Another year passed, and Ms F returned to the same ED, again with chest pain and now complaining of discomfort over her lower left ribs. Dr P, concerned about possible rib fracture, ordered a chest x-ray. No fractures were seen and a diagnosis of costochondritis was made. The right lung nodule was overlooked. The radiologist’s report was completed the following day, noting the right mid-zone nodule, which had increased in size (2.6x2.2cm compared to 2.5x2cm). Follow-up imaging was advised but, once again, the report was not flagged as abnormal to the ED.

Four months on, Ms F visited her GP with a persistent cough, shortness of breath and haemoptysis. She was urgently referred to the respiratory team, who ordered a CT scan. Although the appearance of the nodule was reported as being consistent with a benign pulmonary hamartoma, Ms F underwent biopsy of the nodule, which was found to be malignant. She underwent lobectomy for Stage IIA non-small cell lung cancer but was eventually given a terminal diagnosis.

Claims were brought against the doctors involved in her care. Respiratory consultant Dr K was criticised for failing to identify the nodule on the second x-ray, and failing to

arrange adequate follow-up. Although Dr K’s error would probably have amounted to a breach of duty, experts reviewed the series of images and opined that the growth of the nodule was indolent and likely to have been benign when Ms F was first reviewed. Given that there was no change over a two-year period, she would have been discharged without follow-up by Dr K anyway, thus providing Dr K with a potential causation defence.

Dr A in the ED was alleged to have been negligent in his assessment. The claimant stated that the nodule should have been noted and referred directly to a respiratory specialist for further evaluation. However, experts supported the management as appropriate, and confirmed that even if Ms F had been referred, then the prognosis would likely have been the same.

Systemic failures at the hospital were noted and the radiology department was criticised for failing to have an adequate notification system in place to follow up on abnormal x-rays. The hospital took the position that the individual doctors involved in the care of Ms F should have personally followed up the x-rays they requested.

The case eventually went to trial, where Medical Protection successfully defended the case on behalf of Drs A and K.

### LEARNING POINTS

- Patients may not admit to themselves that they are smokers if they ‘only smoke socially’. During respiratory consultations, specific questions about smoking history should be asked and documented.
- In the UK, the Royal College of Radiologists standards of practice<sup>1</sup> recommend that radiologists are responsible for flagging reports when an alert is required, but it is the responsibility of the organisation to ensure that failsafe systems are in place to ensure appropriate reporting and follow up takes place. Failsafe systems are a “safety net” and do not remove responsibility from the referring clinician to ensure that all reports of requested examinations are reviewed and acted upon. If adequate systems are not in place to ensure appropriate reporting and follow-up, doctors should raise concerns in line with local guidance.

### REFERENCES

1. Royal College of Radiologists, Standards for the communication of radiological reports and fail-safe alert notification (2016)

**M**s F, a 28-year-old social smoker with a history of childhood asthma, presented to the Emergency Department (ED) complaining of low central chest pain and mild shortness of breath. She told the attending doctor that she was a non-smoker, despite smoking five cigarettes daily for a ten-year period. A chest x-ray was performed during her assessment, which revealed a nodular opacity in the mid-zone of the right lung. She was treated for an upper respiratory tract infection and discharged with respiratory follow-up.

Two weeks later she was reassessed by consultant respiratory physician Dr K. He repeated the chest x-ray with two views, which he interpreted as normal. Ms F again maintained that she was a non-smoker when asked. Dr K advised Ms F that the nodule seen on the original ED image was likely to have been an inflammatory nodule that had resolved spontaneously. Since she was



Claim

# A sight for sore eyes



BY DR ANUSHA **KAILASANATHAN**, CONSULTANT OPHTHALMOLOGIST

**D**r P, an ophthalmologist with expertise in laser refractive surgery, performed bilateral Lasik procedures to correct myopic astigmatism on Mrs A, a 33-year-old recruitment consultant. Prior to the procedure Mrs A had best corrected visual acuities of 6/5 in both eyes. She had a history of dry eyes treated with topical lubricants twice a day.

The refractive surgery was uneventful, but five days postoperatively Mrs A started developing eye pain and worsening vision. She contacted Dr P two days later and was seen within four hours. Her visual acuity had deteriorated to 6/36 in each eye. Dr P diagnosed severe bilateral infectious keratitis, took microbiological culture samples and started her on broad-spectrum topical antibiotics. Culture identified *Streptococcus pneumoniae*, sensitive to the prescribed antibiotics, and the infection settled after a prolonged course of treatment. However, Mrs A was left with residual corneal scarring and exacerbation of her pre-existing dry eyes that were difficult to manage and took more than five years to stabilise.

At the last follow-up she required frequent topical lubricants to control her symptoms of dry eye. She was intolerant of contact lenses and required spectacles to achieve her best visual acuity. Her uncorrected visual acuities were 6/9 in both eyes, which improved to 6/6 with spectacles.

Mrs A brought a claim against Dr P, alleging problems with extended close reading, computer work and night driving due to glare, blurring and sensitivity. She also claimed that she suffered post-traumatic stress disorder (PTSD), requiring psychiatric consultation and intervention as a result of her experience.

Mrs A further alleged that the surgery should not have been performed due to her pre-existing dry-eye disease and that she did not give informed consent for the procedure. She also alleged that Dr P failed to ensure that the surgical pack was sterile before the procedure. She claimed that Dr P provided substandard postoperative care, had failed to explain the nature of the complications and had given her no indication of the prognosis.

Mrs A said she lived in fear of becoming permanently blind and had no support from Dr P or his team while she was recovering, adding that he ignored the impact the symptoms were having on her life and did not show any concern for her deterioration. She was unable to plan her future, lost her confidence and ability to function both at work and at home.

It was alleged that Mrs A would have rapidly progressed in her career if not for her visual problems, which prevented her from returning to work on a full-time basis and taking on responsibilities that involved night driving.

### EXPERT OPINION

Dr P contacted Medical Protection, who requested Dr P's clinical records from his preoperative discussions with Mrs A. These showed that Mrs A was informed of the risks of infection and worsening of the dry eye condition, and that she was consented appropriately. Surgical records showed that the surgical pack was checked and documented as sterile by theatre staff pre-operatively as routine.

Expert ophthalmology opinion was supportive of this part of the care provided by Dr P. However, the expert was critical of some aspects of Dr P's postoperative care, concluding that he should have invested more time in the doctor-patient relationship once a serious complication developed and that this aspect of Dr P's care was below the standard expected of a doctor. Mrs A was severely traumatised by the surgical complications and suffered PTSD. An expert in psychiatry took the view that the PTSD may have been lessened had Dr P communicated sensitively, and addressed her concerns adequately and in a timely manner.

### OUTCOME

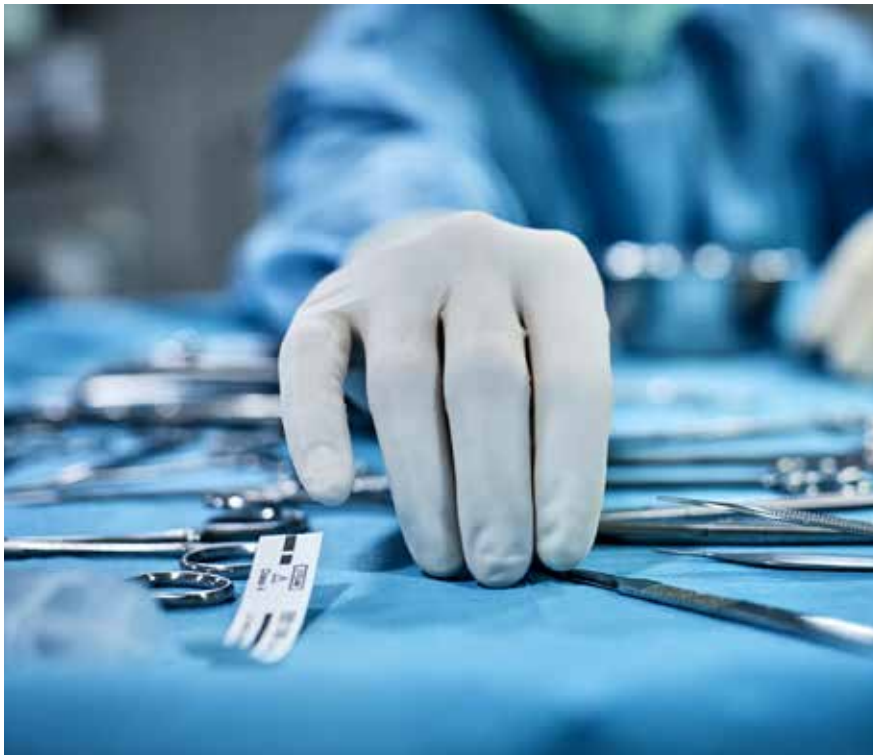A member of the Medical Protection legal team accompanied Dr P to a joint settlement conference, where a compromise was reached and a moderate sum accepted by Mrs A, which covered losses to past earnings, expenses incurred during her recovery period and future losses resulting from the delay to career progression.

### LEARNING POINTS

- Poor outcomes are often a precipitating factor for litigation. However, only a small fraction of such cases end up in litigation and not all cases of successful litigation are a result of medical negligence. In England and Wales, since *Bailey v Ministry of Defence*, in order to establish causation a claimant only has to prove that substandard care has materially contributed to the poor outcome. 'Material contribution' is one that has made more than a minimal difference to the outcome; as each case is decided on its own facts, it's not possible to clarify what is more than a

minimal difference, although the bar is generally set very low.

- Good record-keeping is key to a successful defence when responding to complaints about care. This applies to both clinical and non-clinical concerns and how they were addressed.
- Doctors who have had a negligence claim are more likely to face litigation again even if the medical care they provide is no different from their peers. Complaints against these doctors are usually related to the quality of their communication. Key elements of effective communication include the following:
  - Consultations should be directed towards meeting patient expectations. Use the consultation to build rapport, confirm patient understanding, address misconceptions and make joint decisions about care.
  - The consenting process should give clear, accurate information about risks and outcomes that are personalised to the patient's needs, requests and expectations, and it should be recorded as such. Making assumptions about what the patient wants may lead to misunderstandings. When discussions are complex, consider summarising the discussion with a written letter to the patient, and including the family in discussions if the patient agrees. Give the patient time and space before making a decision when possible.
  - Open and honest discussions when complications arise may reduce the risk of litigation. Showing empathy, being available to address concerns, acknowledging the patient's experience, taking responsibility by offering an apology if appropriate, and feeding back to the patient the lessons that have been learned and the steps taken to reduce the risk of further similar errors, may reduce the psychological impact of an adverse event on a patient.
- Medical Protection offers workshops and e-learning modules on record-keeping, communication skills and consent – visit [medicalprotection.org](http://medicalprotection.org) to find out more.



Claim

# A cyst in time



BY DR ELLEN WELCH, GP

**M**rs D was a 59-year-old clerical worker who presented to her GP with a longstanding lesion on her scalp. She had 'had it for years' but felt it was starting to get bigger and catching on her comb. GP Dr N diagnosed it as a small 7-8mm sized sebaceous cyst and listed her for removal on the minor surgery list.

Dr N removed the lesion successfully on his minor surgery list a few months later. He did not send the excised material to histology for further analysis.

Almost one year later, Mrs D re-presented to the surgery with another cyst on her scalp, about the size of a marble. GP Dr C prescribed antibiotics for an infected sebaceous cyst, but the swelling persisted and two months later, Mrs D again requested removal of the cyst, and Dr C removed it on his minor surgery list. He also did not send the tissue to histology.

Mrs D noticed ongoing discomfort around the scar on her scalp and came back to the surgery three months later to see GP Dr H. He noticed an unusual appearance to the scar, describing an inverted pit with surrounding induration and tenderness. He also discovered a solitary gland in the posterior triangle of the neck. A referral was made to the plastics team.

The plastics team reviewed Mrs D two months later, noting a tethered hypertrophic scar, for which conservative scar management was advised. An ultrasound scan was performed on the neck nodes, which showed these were likely to be reactive nodes due to the recent surgery. The histopathology results for the two prior excisions were requested from the GP

practice to be discussed at the follow-up appointment three months later.

The practice replied, stating that samples had not been sent to histology. Mrs D returned for her three-month review with plastics, and the neck nodes had enlarged, prompting the plastics team to initiate referral for further investigations.

Mrs D was diagnosed with an aggressive, poorly differentiated apocrine adenocarcinoma, with widespread metastases. Despite surgery and adjuvant radiotherapy, she was found to have multiple lung nodules and she died in a hospice a year later.

The GPs at Mrs D's practice were criticised for failing to send the samples they excised for histological examination. Experts agreed that, had they done so, Mrs D would have had an earlier diagnosis and received curative treatment, and her life expectancy would not have been negatively affected.

Mrs D's husband lodged a claim against both GPs involved. As Mrs D had been a higher earner than her husband, there was a notable financial dependency claim. There was also a significant future services dependency claim, including childcare Mrs D would have allegedly provided to her grandchildren.

Although the claim was deemed indefensible, the Medical Protection legal team viewed the claim for future services as being overstated in particular, and was able to negotiate a 50% reduction in the amount being claimed. As with any indefensible claim, we aimed to resolve matters as quickly as possible, and it was eventually settled for a substantial sum.

## LEARNING POINTS

- Apocrine adenocarcinoma is a rare diagnosis with few cases reported in the literature. They are typically slow growing and indolent, presenting as an asymptomatic, slow growing mass. Most patients report the presence of a longstanding lesion before the diagnosis is made. More than half of all patients have lymph node metastases at the time of diagnosis.
- When performing minor surgery, all samples excised should be sent for histological examination. Following this, practices should have robust systems for handling the histology results and ensuring they are actioned, if necessary, and patients informed of the results.
- It is important for GPs to maintain their skills in minor surgery by regularly updating or enhancing their training. Courses are available from a variety of sources.



## Regulatory

# Who else is in the room?



BY DR GERARD MCKEAGUE, GP

**M**rs D, a 56-year-old civil servant, was admitted for a colonoscopy. She had presented with a two-month history of intermittent dull left hypochondrial pain, flatulence, bloating and loose stools. On two occasions she had painless bright red rectal bleeding. Blood tests were essentially normal, apart from a mild increase in her inflammatory markers.

The gastroenterologist, Dr K, suspected diverticulitis and planned to carry out the procedure himself, along with a biopsy if required. Dr K discussed the colonoscopy and its possible complications with Mrs D and obtained her consent. As part of the usual preparation for the procedure, Mrs D was given conscious sedation with fentanyl and midazolam.

Dr K carried out the colonoscopy in accordance with standard practice, and found multiple diverticulae and a small polyp in Mrs D's descending colon, which he removed for histopathology.

One week later, Mrs D submitted a formal complaint to the hospital. She complained about Dr K's disregard for her modesty, the extreme distress she experienced while undergoing the procedure and the inappropriate hospital environment in which the colonoscopy took place. In the endoscopy room she said she had overheard unknown male voices, who she presumed were IT staff, close by. These male voices, she said, were laughing inappropriately and commenting on details inside the room.

During the procedure Mrs D was obviously in a state of undress and she complained that this had caused her extreme upset both at the time and when she reflected on

it later. She understood that a doctor and a nurse would be present throughout the colonoscopy, but when she overheard men's voices discussing non-clinical matters like repairing computers and a printer, this was unacceptable to her while she was physically exposed.

Dr K confirmed that he had personally consented Mrs D and advised her of the usual risks and complications. He also confirmed that while the patient was getting prepared for colonoscopy, it was normal practice for them to be covered by a blanket or sheet so there would be no unnecessary exposure of intimate body areas. This, he said, had been explained to Mrs D before she'd been sedated.

It was possible, Dr K said, that Mrs D had overheard Dr K talking to another staff member, Mr D, an IT technician, in the corridor before the procedure, but at no time was there another male present in the room either before or during the colonoscopy. Dr K would, he said, have sought Mrs D's consent before including any other male staff members in the room. But as it was, Dr K and the female nurse were the only personnel in the room with her.

The patient complained to the Medical Council and Dr K sought the assistance of Medical Protection. We assisted him in preparing a full explanation in response to the Medical Council and the complaint was dismissed with no further action.

### LEARNING POINTS

- Don't forget that patients can sometimes overhear medical staff having conversations while invasive procedures are taking place. It is possible that, under pressurised conditions, when patients are feeling vulnerable, these might be misunderstood by the patient. Many sedatives can also cause anterograde amnesia, so memories can be unreliable.
- It is important to inform patients if other staff members, eg medical students, may be present at the time of these procedures.
- Don't make any assumptions about patients' expectations of procedures. It may be necessary to be explicit about seemingly obvious matters, such as the degree to which a patient may be exposed during a procedure.

YES

NO

Regulatory

# Questioning your consultant



BY DR ELLEN WELCH, GP

**M**r A, a 68-year-old pensioner, was diagnosed with bowel cancer after experiencing rectal bleeding and a change in bowel habit. He was investigated under the care of consultant surgeon Mr S, and scheduled for a local excision of a sigmoid mass.

Ms X, a year 5 specialty trainee working on Mr S's team, performed the surgery. On opening Mr A's abdomen, she found an unexpected mass adherent to the bladder, so called consultant Mr S to take over. Mr S proceeded to excise the mass. While assisting with the procedure, Ms X raised concerns that the mass they were working on was not the tumour they were initially aiming to remove, as it appeared anatomically too high. She pointed out that the preoperative investigations suggested the tumour was more distal. Mr S disagreed, continued to excise the mass, created a colorectal anastomosis and left Ms X to close.

Histology verified a sigmoid diverticular mass and evidence of cancerous cells in the donut of tissue removed from the rectum. The case was discussed with the whole team at MDT and Mr S instructed Ms X to advise the patient that further surgery was likely to be necessary, due to the microscopic evidence of retained tumour.

Mr A was readmitted a month later and underwent further surgery under the care of Mr S's team (on this occasion, Ms X was not involved). While recovering on the surgical ward, Mr A was assaulted by another patient and sadly died of a subdural haematoma.

An inquest and subsequent trust investigation was held into Mr A's death, during which Mr S was criticised for his oversight in excising the wrong mass during the earlier procedure and was referred to the Medical Council for investigation.

Ms X, who was not interviewed during either the inquest or trust investigation, raised the case with her educational supervisor and it was discussed as part of her appraisal.

Three years later, Ms X was contacted by the Medical Council and was informed they were investigating concerns that had been raised about her involvement in the care of Mr A. She contacted Medical Protection, who responded on her behalf, stating that Ms X was not the lead surgeon in the case and that she had raised concerns with Mr S during the procedure that he had excised the wrong mass. Mr S did not recall Ms X raising these concerns. As there were significant differences in the evidence offered by Ms X and Mr S, further investigation was anticipated.

Eighteen months later, Ms X received a letter from the Medical Council. Case examiners at the Medical Council advised that the enquiry into Ms X could conclude without further action. Despite the unresolved differences in evidence given, they took into consideration the extensive reflections she had made regarding the case for her appraisal. Her career had continued to progress during the period of investigations, and she'd had no further adverse events.

## LEARNING POINTS

- 'Calling out' a senior colleague is difficult and where there may be clinical uncertainty, it is easy to defer to a more senior colleague. However, whichever stage in training a doctor is at, there remains a duty of patient advocacy and Ms X correctly questioned the procedure they were undertaking on Mr A. Medical Protection's factsheet on *Raising Concerns and Whistleblowing* looks at the issue in more depth – although this is a UK factsheet, the general principles apply anywhere in the world.
- As the named consultant for the case, Mr S had overall responsibility for the care given, and made the treatment decision, which ultimately resulted in Mr A's readmission and subsequent surgery. It was during this readmission that Mr A was assaulted, leading to his untimely death. In these circumstances, the law takes the view that, although the doctors could not have anticipated the assault, nor had any control over it, the fact remained that due to the inadequate primary procedure, the patient found himself back in hospital where he then suffered a fatal injury.
- Written reflections by a doctor, along with clear and contemporaneous records, following an adverse event may influence the Medical Council case examiners' decision whether or not a case can be closed without referral to a fitness to practise hearing.



# Nausea and weight loss – what's the cause?



BY DR GERARD MCKEAGUE, GP

**M**rs H, an overweight 52-year-old schoolteacher, presented to her local GP, Dr W, with symptoms of nausea, fatty food intolerance and epigastric discomfort. It had started six weeks before, while she was on holiday, and was now getting worse, usually occurring when she tried to eat spicy or fried meals.

Mrs H said that sometimes she would get heartburn and take antacids, but they had made little difference. While she had been on holiday she had a brief attack of diarrhoea, which had now settled, but she thought she might have been infected by a "parasite". She also mentioned stress that she was experiencing due to work. She was an occasional smoker and drank two to three glasses of wine per night with her evening meals.

Dr W recorded Mrs H's BMI as 39, examined her abdomen and noted her history and his findings of a mildly tender epigastric/right upper quadrant area, with no fever, guarding, or signs of jaundice, and a temperature of 36.7. He recorded no family history of significance. He provided smoking cessation advice, asked her to reduce her alcohol intake and encouraged exercise. Dr W also prescribed a proton pump inhibitor for Mrs H and arranged for an ultrasound of her liver, a full blood count and amylase and liver function tests, as he suspected she had gallstones and might have been experiencing biliary colic.

Dr W advised Mrs H that he would contact her if the results were abnormal and that she should come back in a month if her symptoms persisted. The ultrasound and blood tests were normal and three

months later Mrs H returned, to say that the treatment had initially helped but that now she was once again experiencing intermittent nausea; and when she had stopped the PPI, her dyspepsia had returned. She had successfully stopped smoking and reduced her alcohol intake. Dr W examined her again, noting similar findings to the initial consultation. Rectal examination was normal. He increased the dose of her PPI and recorded that a referral for gastroscopy should be considered if things didn't improve after a further month's treatment. He checked another full blood count, and amylase and liver function tests, all of which were once again normal.

Two months later, Mrs H presented with 5kg weight loss and worsening nausea and dyspepsia. The abdominal discomfort had not changed and examination showed a soft abdomen with no palpable masses.

Dr W repeated her blood tests and made a red flag referral for her to the local gastroenterologist. An urgent gastroscopy was arranged, which found a gastric carcinoma. A CT scan showed evidence of metastatic spread to Mrs H's liver and mesenteric nodes.

Mrs H commenced a course of chemotherapy but died six weeks later. Her husband complained to the Medical Council that her diagnosis was delayed through negligence on the part of Dr W and that if she had been referred earlier for investigations, her death could have been avoided.

The Medical Council produced a critical expert report which supported this. Dr W, it stated, should have taken into consideration the patient's age and risk factors for gastric cancer, and made a red flag referral for her on the second visit. Medical Protection challenged this account, citing the comprehensive records made by Dr W displaying his adherence to national guidelines and the case was dismissed.

## LEARNING POINTS

- Dr W made clear notes of his findings and plan for further management if it was required. His clinical decisions based on his findings at the time were transparent and appropriate, and he made arrangements for 'safety netting' with the patient. He referred to local and national guidelines for the treatment of dyspepsia.
- Risk factors for gastric cancer include, amongst others, a positive family history, smoking and excessive alcohol consumption. In this case the only relevant risk factors were smoking and alcohol (and the possibility of *H. pylori* infection, given the dyspeptic symptoms).
- Clinical presentation of patients with gastric cancer is often vague and non-specific. Symptoms include nausea and dyspepsia as in this case, and weight loss is often indicative of late stage disease.





# Over to you

## Strong record-keeping – strong defence

I found the article “Strong record-keeping – strong defence” in the latest edition of Casebook rather depressing.

The care provided by Dr G was exemplary. The consent process was thorough and well documented. The complication was identified and managed rapidly, and communication with the patient and the surgical team was excellent. Dr G even accompanied the patient in the ambulance during transfer and visited her several times following surgery. I cannot think what more he could have done in caring for this patient.

Despite all this the patient still brought a medical negligence claim against Dr G and reported him to his Medical Council. Although with the help of Medical Protection these claims were not continued, Dr G would not have been unscathed by this episode. It must have been extremely stressful for him to have had these claims to defend. Experiences such as this lead to burnout in excellent clinicians like Dr G.

**Dr Bronagh McKay**



*Stress and burnout has always been part of everyday life for healthcare professionals, who are under particular pressure because of the responsibility of the job. However, we are only too aware at Medical Protection of the stresses caused by receiving and dealing with complaints, clinical negligence claims, disciplinary matters, and other medicolegal issues.*

*Medical Protection has a counselling service that was introduced specifically to assist members suffering from stress as a result of such issues. Members who are affected can speak to their case handler for more information.*



## Comprehending your medication

I was interested to read Dr McEnergy's letter in the June 2018 *Casebook*. I have always thought that the information sheet in each pack of medication was there to protect the drug company rather than to help the patient. I think most of the leaflets I have looked at are beyond the reading ability and comprehension of most patients, and it is incumbent on the prescribing physician to ensure that the patient has sufficient information.

As an example, I scanned one patient information leaflet into my computer, and checked the readability level in Microsoft Word. The leaflet I used was for fluoxetine 20mg from Bristol Laboratories.

The Flesch-Kinkaid Grade level was 11.7, which I think equates to a reading age of about 18. The average for the UK is 9, and for the *Guardian* newspaper is about 14. For the vast majority of the population, this document would be incomprehensible. It was also over 4,000 words, which is a long read.

Why do we continue to permit the drug companies to hide behind these documents – no physician should rely on his or her patient being able to read and comprehend them.

**Dr John McGough**

## A missed diagnosis?

As a dermatologist I read the case about Mrs M (“A missed diagnosis but no negligence”) with a mix of interest and unfolding horror.

It appears to me that the patient saw a dermatologist who made a correct diagnosis of eczema/nodular prurigo. She then saw another dermatologist who made an incorrect diagnosis of scabies (as treatment didn't work). How or why therefore is this “a missed diagnosis” as described in the title on page 6?

It is worrying that one doctor could make a sensible or correct diagnosis and then another doctor make an incorrect one and the former be sued!

Dermatology is a very clinical specialty – often we don't know the diagnosis or have a range of differential diagnoses, or the clinical picture changes over time – again changing the diagnosis. How worrying for us in light of this case.

I can't see why this has been labelled as a missed diagnosis in *Casebook* however.

**Dr James Powell**



*Thank you for your comments about the title of the case report “Missed diagnosis but no negligence” in our June 2018 edition of Casebook.*

*Looking back at this case I note the expert concluded that there was “suspicion but no proof that scabies may have been present at some point”, and it is probably on this basis that the case was given its heading. I agree, however, that the diagnosis was less certain than this and that the heading gave the impression it was definitely missed. I hope this did not detract from the content of the case and the important learning point that the careful examination and documentation by the member meant that we were able to successfully defend her against the allegation of a missed diagnosis.*

*Many thanks once again for your comments on this case.*



**We welcome all contributions to *Over to you*.**  
**We reserve the right to edit submissions.**



**Please address correspondence to:**

Casebook Editor, Medical Protection, Victoria House, 2  
Victoria Place, Leeds LS11 5AE, UK.  
Email: [casebook@medicalprotection.org](mailto:casebook@medicalprotection.org)

# ONLINE LEARNING PRISM

Support your career development with our online learning platform, Prism, which offers interactive modules that can be accessed at a time and place to suit you.

- Free to all members
- Interactive content produced for doctors by doctors
- Track your learning and download certificates in your personal account
- Accessible via desktop, tablet and mobile 24/7



Register now and start your online learning with **Prism** today.

Visit [medicalprotection.org/prism](https://www.medicalprotection.org/prism)

# CONTACTS

## You can contact Medical Protection for assistance [medicalprotection.org](https://www.medicalprotection.org)

### Medicolegal advice

#### Hong Kong

Freecall 800 908 433 | [querydoc@medicalprotection.org](mailto:querydoc@medicalprotection.org)

#### Malaysia

Freecall 1800 815 837 | [querydoc@medicalprotection.org](mailto:querydoc@medicalprotection.org)

#### Singapore

Freecall 800 616 7055 | [querydoc@medicalprotection.org](mailto:querydoc@medicalprotection.org)

### Membership enquiries

#### Hong Kong

Freecall 800 908 433 | [wendyh@hkma.org](mailto:wendyh@hkma.org)

#### Malaysia

Freecall 1800 815 837 | [insurance@mma.org.my](mailto:insurance@mma.org.my)

#### Singapore

Freecall 800 616 7055 | [mps@sma.org.sg](mailto:mps@sma.org.sg)

### Medical Protection

Victoria House  
2 Victoria Place  
Leeds LS11 5AE  
United Kingdom

### [info@medicalprotection.org](mailto:info@medicalprotection.org)

In the interests of confidentiality please do not include information in any email that would allow a patient to be identified.



The Medical Protection Society Limited (“MPS”) is a company limited by guarantee registered in England with company number 36142 at Level 19, The Shard, 32 London Bridge Street, London, SE1 9SG.

MPS is not an insurance company. All the benefits of membership of MPS are discretionary as set out in the Memorandum and Articles of Association. MPS® and Medical Protection® are registered trademarks.